

# Nerve Conduction Studies and Electromyography in the Evaluation of Peripheral Nerve Injuries

DIANNA QUAN, M.D. AND SHAWN J. BIRD, M.D.

**Abstract:** Peripheral nerves are susceptible to a variety of injuries, often with coexistent orthopaedic trauma. Although the presence of nerve involvement in many circumstances may be clinically obvious, an appropriate therapeutic approach depends on more detailed information regarding the nature of the lesion. Electrodiagnostic studies (nerve conduction studies [NCS] and needle electromyography [EMG]) can provide precise information about the localization and severity of the nerve injury. These are particularly helpful when the clinical examination is limited by pain or poor effort on the part of the patient. In the case of severe injuries, these studies may provide evidence of nerve continuity. They also provide information about prognosis, allowing one to reliably estimate the timing and extent of recovery. Intraoperative studies, when performed at the appropriate time, may determine the need for nerve grafting.

## Introduction

Acute peripheral nerve lesions frequently accompany orthopaedic trauma. The peripheral nerve has a limited repertoire of response to nerve injury (Fig. 1). Mild focal compression causes segmental injury to the Schwann cells that myelinate nerve axons. With more severe trauma, axons, as well as their myelin sheath, are injured. This leads to degeneration of the distal axon fragment and reactive changes in the cell body, a process known as Wallerian degeneration.

Recovery from peripheral nerve trauma may occur by three mechanisms, i.e., remyelination, collateral sprouting of axons, and regeneration from the proximal site of injury. Remyelination is the fastest of these reparative processes, occurring over 2-12 weeks, depending on the extent of the injury. Following degeneration of injured distal axon fragments, collateral sprouts from intact neighboring axons may provide innervation to denervated muscle fibers. This process takes between 2 to 6 months. In cases of severe axonal injury, collateral sprouting is not sufficient to provide innervation to all muscle fibers. Further clinical recovery depends on regeneration from the proximal site of injury, which may require up to 18 months.

Nerve conduction studies (NCS) and needle electromyography (EMG) are complimentary techniques that are to-

gether often termed EMG, although strictly speaking this refers only to the needle part of the studies. These tests are essential in the evaluation of nerve disorders. They are helpful in localizing the site of injury, such as differentiating lower cervical root, lower trunk of brachial plexus injury, or ulnar neuropathy. They allow distinction of conduction block (neurapraxia) from axonal degeneration. They also provide important prognostic information for guiding patient management. An understanding of nerve response to injury determines the optimum time for these studies to be performed.

Electrophysiologic testing, like the clinical examination or arthroscopy, is dependent on the skills of the examiner. In an individual patient, the approach is designed to extend the physical examination and must be redirected during the course of the study by the initial electrodiagnostic findings. Therefore, these studies are best performed by physicians trained in EMG and neuromuscular disorders.

## Structure of the Peripheral Nerve

The motor component of the nerve supply to the face and limbs originates from cell bodies located within the cranial nerve motor nuclei and anterior horn of spinal cord gray matter. The cell body or perikaryon gives rise to an axonal process, and groups of axons from each spinal level exit the cord as the ventral motor root. Fibers from adjacent motor roots contribute to the formation of named nerves and their branches. Each individual axon of a peripheral motor nerve terminates at the muscle endplate region, where it supplies (innervates) a large group of muscle fibers. This motor axon and the muscle fibers it supplies is considered the motor unit, an important structural unit in EMG studies and in understanding recovery from nerve injury. Contraction of a muscle involves the near simultaneous firing of individual motor axons and muscle fibers they innervate, the motor units.

Sensory nerve cell bodies, in contrast, reside in dorsal root ganglia outside the spinal cord. Two processes extend from the cell body, one forming the axons of the peripheral sensory nerves, the other projecting proximally to second-order sensory neurons in the dorsal aspect of the spinal cord. Peripheral sensory nerves carry afferent impulses from bare nerve endings and specialized receptors to the dorsal root ganglia and then via the dorsal sensory root into the dorsal

---

From the Department of Neurology, University of Pennsylvania School of Medicine, Philadelphia, PA.

Address correspondence to: Shawn J. Bird, M.D., Department of Neurology, Hospital of the University of Pennsylvania, 3400 Spruce Street, Philadelphia, PA 19104.

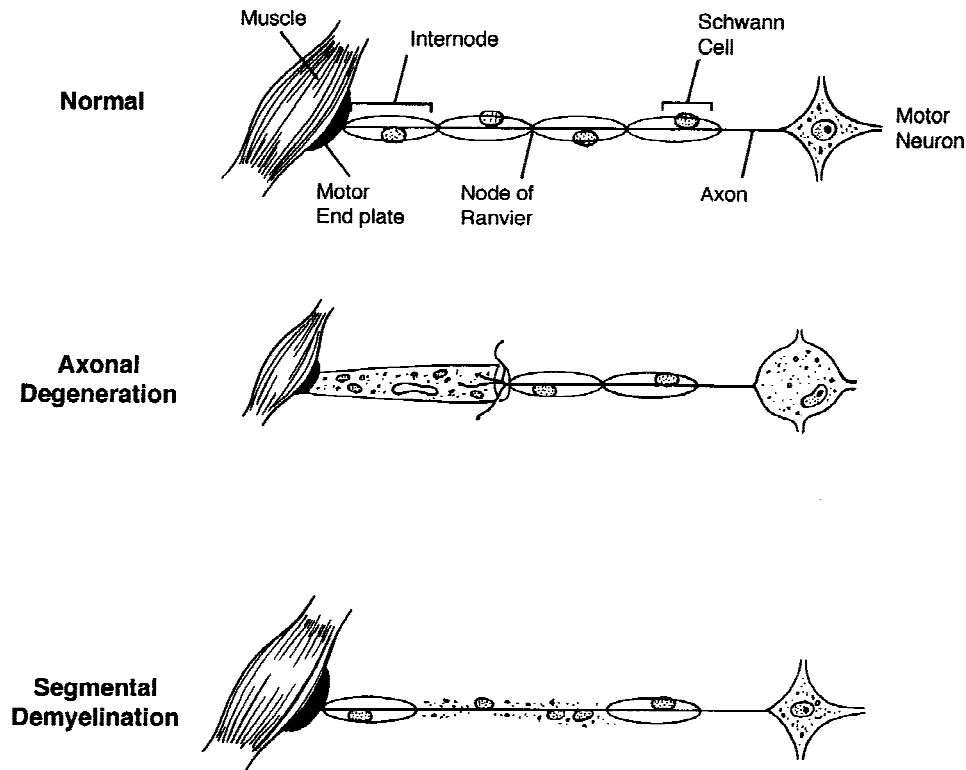


Fig. 1. Normal peripheral motor nerve anatomy and responses to injury.

horn of the spinal cord. Sensory inputs are organized according to a dermatomal distribution, with adjacent spinal levels supplying overlapping adjacent areas of skin and underlying soft tissue.

Both sensory and motor axons are associated with supporting glial cells, the Schwann cells. Unmyelinated axons are wrapped in groups by Schwann cell cytoplasm. By contrast, individual myelinated fibers are surrounded by Schwann cells arranged in series along the length of an axon. The Schwann cell membrane is wrapped tightly around the axon forming the myelin. These myelinated fibers have gaps between the myelin segments, called nodes of Ranvier, that permit nerve action potentials to jump rapidly from node to node (saltatory conduction). Myelinated fibers conduct between 40–70 m/sec, much faster than the 0.5–2.0 m/sec conduction velocity of unmyelinated fibers.

The larger the axonal diameter, the greater the thickness of myelin and the internodal distance. The largest fibers conduct impulses the most efficiently. They mediate functions that require rapid communication, such as efferent motor impulses and proprioceptive feedback from muscle stretch and joint position receptors. Conduction along these fibers is measured during NCS. In contrast, conduction along small, unmyelinated sensory fibers subserving pain and temperature is not measured by routine NCS.

Each peripheral nerve is made up of a bundle of fascicles. Multiple fascicles are held together by epineurium, the outer layer of a peripheral nerve, that contains vessels and more connective tissue. Each fascicle is surrounded by a connective tissue layer, the perineurium. Within the fascicle, myelinated and unmyelinated axons, connective tissue, small

capillaries, and extracellular fluid compose the endoneurium. The tensile strength of the nerve, allowing protection from trauma and compression, is provided by the longitudinally oriented endoneurial and circumferential perineurial and epineurial collagen.

### Response to Nerve Injuries

In 1943, Seddon [1] proposed a classification of peripheral nerve injuries that is still useful today (Table 1). Under this system, three types of injuries are described. The mildest, neurapraxia, refers to the inability of nerve fibers to conduct an action potential despite axonal continuity. Loss of axonal continuity without associated disruption of the fascicular connective tissue elements is referred to as axonotmesis. Neurotmesis describes the most severe injury, with disruption of the entire nerve, including all glial and connective tissue supports. Sunderland [2] proposed a more detailed classification in 1951, further dividing Seddon's axonotmesis category into injuries with intact endoneurium, disrupted endoneurium but intact perineurium, and disrupted inner connective tissue layers with intact epineurium. These axonotmesis injuries of varying severity were designated types 2 to 4, from least to most severe. He referred to Seddon's neurapraxia as a type 1 and neurotmesis as a type 5.

Neurapraxia, or type 1, injuries most often result from compression and subsequent focal demyelination [3]. More severe closed trauma such as crush or stretch injuries may cause axonotmesis of varying degrees. Focal ischemia also may cause axonotmesis. Neurotmesis commonly results

**Table 1.** Traditional classification of peripheral nerve injuries

Seddon	Sunderland	Pathology
Neurapraxia	1	Focal demyelination; block of nerve conduction without axonal degeneration
Axonotmesis	2	Axonal degeneration with intact endoneurium
Axonotmesis	3	Axonal degeneration; endoneurial disruption with intact perineurium
Axonotmesis	4	Axonal degeneration; endoneurial and perineurial disruption with intact epineurium
Neurotmesis	5	Complete axonal degeneration; disruption of all connective tissue elements

from lacerations, or less commonly from severe crush or stretch injuries. All of these nerve lesions may cause weakness and numbness as well as pain and paresthesias [4].

Both axonotmesis and neurotmesis involve separation of the perikaryon from the axon segment distal to the injury. Delivery of essential molecules from the cell body to the axon fragment and of axonal metabolic and signaling products to the cell body is interrupted [5]. Intra-axonal calcium level rises [6]. The separated axon fragment swells and loses electrical responsiveness over 5–12 days in a process known as Wallerian degeneration [7]. Lesions of the axon close to the cell body may result in neuronal cell death, eliminating the chance for recovery of those axons. In most cases, however, only reactive changes of central chromatolysis are seen in the perikaryon [5].

The time required for recovery depends on the type of injury and the relative contributions of three possible modes of recovery, i.e., remyelination, collateral sprouting from surviving axons, and axonal regeneration. Restoration of impulse conduction after neurapraxia depends on remyelination of the affected site. Of all nerve injuries, neurapraxia generally recovers most quickly, usually taking 6–8 weeks [8]. Axonotmesis recovers by two processes. Lesions involving less than 20–30% of motor axons may recover fully by collateral sprouting of remaining axons over 2–6 months. With more extensive injury, surviving axons cannot fully supply the denervated muscle. Nerve regeneration from the proximal axon stump at the site of injury must compensate for the remainder. When more than 90% of axons are injured, regeneration becomes the predominant mechanism of recovery [9,10].

The timing of recovery depends on the distance of the lesion from the denervated target muscle. Proximal regeneration occurs at a rate of 6–8 mm per day, whereas distal regeneration occurs at 1–2 mm per day [11]. The prerequisite for regeneration is an intact Schwann cell basal lamina tube to guide and support axonal growth to the appropriate target muscle. Schwann cell tubes remain viable for 18–24 months after injury [10]. If the axon does not reach its target muscle within this time, these supporting elements degenerate and effective regeneration cannot occur.

We prefer a classification system (Table 2) that reflects both the nature and degree of the injury, but also correlates well with the electrophysiology. This system allows accurate prediction of the mode, timing, and completeness of recovery.

### NCS and Needle EMG

Individual sensory, motor, and mixed nerves can be examined using standard electrophysiologic techniques [10] with measurement of nerve response amplitude and conduction velocity along the course of each nerve. For sensory nerve studies, an individual sensory nerve is electrically stimulated at the skin surface and the sensory nerve action potential (SNAP) is recorded from a separate point on the nerve. The response can be recorded orthodromically with a stimulus applied distally and recorded proximally. Alternatively, an antidromic response can be recorded with the stimulus applied proximally and recorded distally. Small myelinated and unmyelinated C fibers have a 10–20 times higher threshold of stimulation and are difficult to examine reliably. Sensory conduction studies therefore reflect only conduction along the largest myelinated fibers. SNAPs typically are 5–20  $\mu$ V in amplitude. Since sensory nerve response amplitudes are so small, accurate measurement usually requires averaging several responses. Despite careful attention to technique, responses are often unobtainable from small sensory nerves such as the medial and lateral antebrachial cutaneous, saphenous, lateral femoral cutaneous, and medial and lateral plantar nerves, even in normal individuals.

A compound motor action potential (CMAP) may be recorded over muscle after percutaneous stimulation of the appropriate motor nerve. The CMAP represents a summation of motor unit responses beneath the recording electrode and its amplitude is proportional to the number of motor axons stimulated. Like sensory nerve studies, amplitude, latency, and velocity are of interest.

Motor nerve response amplitudes are up to 100 times larger than sensory response amplitudes and require higher stimulus intensities. Also, unlike the sensory latency, the distal motor latency includes the time necessary for trans-

**Table 2.** Preferred pathophysiologic classification and predicted recovery

Type of injury	Mode of recovery	Time to recovery
Conduction block (neurapraxia)	Remyelination of focal segment involved	2–12 weeks
Limited axonal loss	Collateral sprouting from surviving motor axons	2–6 months
Intermediate axonal loss	Collateral sprouting and axonal regeneration from site of injury	2–6 months
Severe axonal loss	Axonal regeneration	2–18 months
Complete nerve discontinuity	No recovery without nerve grafting	2–18 months

mission of signal across the neuromuscular junction. To eliminate this variable from the motor nerve conduction velocity calculation, a second proximal site along the nerve is stimulated. Dividing the distance between the distal and proximal stimulation sites by the difference between the distal and proximal motor latencies yields the conduction velocity.

Needle EMG can be used to distinguish between neurogenic and myopathic causes of weakness. The pattern and extent of EMG involvement can localize neuropathic disorders to anterior horn cells or to individual peripheral nerves or spinal roots. A fine needle electrode inserted into the muscle records electrical activity of motor units at rest and during voluntary contraction. The electrode records surrounding muscle fiber activity for each motor unit as a summated motor unit potential (MUP). The amplitude of the MUP is proportional to the number of muscle fibers in the vicinity of the needle. The duration of the potential relates to the number and location of more distant fibers innervated by the same axon. More distant muscle fibers are often recorded as multiple phases or crossings of the base line. A normal MUP has four or fewer phases.

### Electrodiagnostic Studies Following Acute Nerve Injury

Electrodiagnostic studies are essential for differentiating the loss of function that occurs from axonal loss (axotomy or Wallerian degeneration) from that which results from demyelination (neurapraxia). However, the timing of the studies is critical in obtaining the most information at each stage following nerve injury. The physiologic effects of axonal disruption are well known and take time to be expressed [12]. These studies can also determine the presence of early nerve regeneration, well before this is apparent on clinical examination. The evolution of these changes in NCS and EMG is summarized in Table 3.

After an axon is transected, the process of Wallerian degeneration (Fig. 1) occurs in the distal nerve segment over the course of several days. In the immediate minutes to first several days after nerve transection, the distal axon fragment remains electrically excitable. During this period, stimulation distal to the site of injury may result in normal or mildly abnormal values despite severe proximal nerve injury. Motor axons remain excitable for up to 7 days after injury. Sensory axons remain excitable for up to 11 days [7]. Both responses will be absent after stimulation proximal to the site of injury.

Immediately after injury, the absence of a response to proximal stimulation and normal response to distal stimulation cannot distinguish axonal disruption from conduction block (neurapraxia) due to focal demyelination, injuries that have very different prognoses for recovery. After 10–12 days, however, the difference becomes clear. In the case of axonal injury, Wallerian degeneration will have occurred with the resultant failure to obtain sensory and motor responses with distal stimulation. In contrast, distal responses are preserved in focal demyelination because the underlying

axons are intact. Conduction velocity may be slowed, reflecting loss of vulnerable large diameter, rapidly conducting axons. Therefore, if an acute nerve injury is suspected and nerve continuity is in question, it is best to perform nerve conduction studies 10–14 days after the injury [12]. Identification of conduction block with a preserved distal response amplitude allows one to reliably predict a rapid and complete recovery.

On the needle EMG examination, changes after axonal injury and Wallerian degeneration follow an even more protracted time course. EMG changes evolve over weeks and months, rather than days as seen with NCS. Without normal trophic influences from nerve, muscle displays abnormal electric irritability in the form of spontaneous fibrillation potentials, positive sharp waves, or fasciculations. Spontaneous electrical activity in muscle fibers develops 2–6 weeks after denervation and continues until the muscle fiber degenerates completely or is reinnervated by nerve. The presence of spontaneous activity therefore indicates axonal loss that is at least 2–6 weeks old or reflects ongoing nerve injury. No spontaneous electrical activity is seen in muscle on EMG with demyelinating lesions since the muscle still receives trophic support from the intact axon.

During voluntary contraction, the amplitude, duration, rate of firing, and recruitment pattern of MUPs provide information about the progress of nerve regeneration and the chronicity of injury (Fig. 2). Normal muscle contraction results in an orderly and graded recruitment of motor units. Small units are recruited first. With further contraction, these units fire slightly faster. However, increasing contractile demands are met primarily by recruitment of larger units until all available fibers are working to generate a full interference pattern of motor units and full contractile force.

Immediately after axonal injury, the muscle is weak because the number of motor units available to generate contractile force is reduced. There is no change in the configu-

**Table 3.** Timing of electrodiagnostic studies after peripheral nerve injury

Timing of study	Information obtained
Baseline study (0–7 days)	Usually unnecessary Base line for later comparison Documents nerve continuity with presence of voluntary motor units on EMG
Initial study (10–21 days)	Distinguishes lesions with predominant demyelination from those with substantial axonal loss Assesses extent of axonal loss (reduced CMAP amplitude and number of motor units recruited with maximum effort)
Follow-up study (3–6 months)	Documents extent of reinnervation in markedly weak muscles If necessary, intraoperative studies assess presence of axonal regeneration through the injured segment
Follow-up study (6–12 months)	Documents extent of reinnervation in muscle at greater distance from site of injury

ration of MUPs, indicating that the nerve injury is acute and that reinnervation has not yet occurred. To generate maximum force, remaining units can only fire faster.

Early collateral nerve sprouting occurs from surviving motor axons to resupply muscle fibers that have lost their motor axon (Fig. 2). This can be identified electrically on EMG by the presence of small, polyphasic satellite potentials following a normal MUP and long-duration polyphasic MUPs with relatively normal amplitudes. Excessive numbers of polyphasic units in the setting of reduced numbers of rapidly firing motor units suggest subacute nerve injury and early collateral sprouting and axonal regeneration. As the newly formed axonal sprouts mature, their electrical contribution is incorporated into the parent motor potential, resulting in an abnormally long and large MUP.

**Timing of Electrodiagnostic Studies**

The degree and location of axonal injury are the primary determinants of recovery time (Table 3). In the first 10 days after injury, NCS and EMG can determine only if a nerve injury is present. Since Wallerian degeneration has not yet occurred, the mechanism of injury and therefore the prognosis are difficult to assess. In focal demyelination with conduction block or neurapraxia, even severe initial weakness may recover significantly within 2 months. Mild or moderate axonal loss improves by collateral sprouting, which takes 2–6 months. With severe axonal injuries, par-

ticularly those involving complete transection of a nerve, improvement in strength requires at least some regeneration from the site of injury. This process may be inefficient and continue for up to 24 months until the collapse of Schwann cell tubes or may terminate prematurely in neuroma formation.

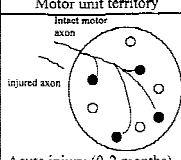
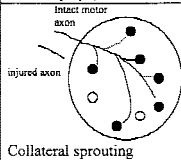
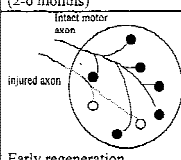
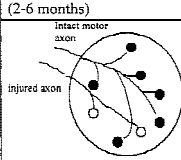
When clinical recovery fails to occur within the expected time, EMG is useful to identify the earliest signs of reinnervation by regenerating axons. This is important when nerve graft is a possible option, since grafting must take place before Schwann cell tubes no longer support nerve regrowth. If incipient muscle reinnervation has begun, however, nerve grafting has no advantage. Similarly, EMG identifies situations in which no further nerve recovery is expected. A suggested approach to the timing of these studies is detailed in Figure 3.

**Intraoperative Peripheral Nerve Studies**

The use of intraoperative nerve conduction studies is an important improvement in the surgical treatment of peripheral nerve injuries that are in continuity [13,14]. When the nerve is transected, whether the surgery is a primary or a delayed repair, the decision to use a nerve graft or to reanastomose the proximal and distal stumps is determined by the width of the gap and the status of the nerve stumps. In this setting there is no need for physiologic monitoring.

In the case of nerves that are severely injured but still in continuity, some fail to regenerate adequately. It is in these circumstances that intraoperative physiologic studies are well suited. For those patients who have evidence of early reinnervation on conventional EMG (by 6–9 months), there is no need for nerve grafting (Fig. 3). Recovery is always better when reinnervation is by nerve regeneration from the site of injury rather than through a nerve graft. When the target muscle to be reinnervated is relatively close to the injury, then it is prudent to wait for evidence of regeneration on standard EMG. The time for the axonal sprouts to reach the muscle can be estimated given an approximate rate of nerve growth of 1 mm per day. However, when a greater distance needs to be traversed by nerve regeneration, EMG evidence of axons reaching their target muscle may be delayed for 12–24 months. By waiting that long to decide that there was no spontaneous regeneration, it would be too late to use nerve grafting. The distal Schwann cell tubes no longer support nerve regeneration beyond approximately 18 months. Intraoperative studies allow the surgeon to get information earlier about the presence or absence of axonal regeneration through the site of the injury.

The operative studies can be performed 6–9 months after the injury [15]. After exposure of the damaged section of nerve, bipolar electrode pairs are applied to the nerve and are used to stimulate and record from the exposed nerve trunk. Stimulation is performed as far proximal to the estimated proximal site of injury as possible. The recording pair of electrode records a nerve action potential (NAP). If this NAP is obtained beyond the injured segment, then axonal regeneration has occurred successfully through this seg-

Motor unit territory	NCS	EMG	Clinical strength
 <p>Intact motor axon injured axon Acute injury (0-2 months)</p>	Decreased amplitude	Normal morphology motor unit potentials  Decreased number of motor unit potentials	Reduced proportional to axonal loss
 <p>Intact motor axon injured axon Collateral sprouting (2-6 months)</p>	Decreased amplitude	Motor unit potentials with increased polyphasia  Decreased number of motor unit potentials	Early recovery of contractile force
 <p>Intact motor axon injured axon Early regeneration (2-6 months)</p>	Decreased to normal amplitude	Motor unit potentials with increased polyphasia and increased amplitude  Decreased number of motor unit potentials	Further recovery of contractile force
 <p>Intact motor axon injured axon Mature regeneration (2-18 months)</p>	Normal amplitude	Motor unit potentials with increased amplitude and duration  Decreased number of motor unit potentials	Normal strength

**Fig. 2.** Electrodiagnostic findings in partial axonal loss. Open circles represent muscle fibers originally innervated by the injured axon. With collateral sprouting from the intact axon, the motor unit enlarges (dark circles and intact axon). Eventually, the proximal end of the injured axon innervates some of its former muscle fiber territory.

ment. Nerve grafting is not necessary, and likely detrimental, in this circumstance. If no NAP is obtained, the segment can be resected and a graft inserted instead. The proximal site of injury can be identified where the most distal NAP can be obtained, and the nerve can be divided at that point. This may be quite helpful where the intraneural injury is more proximal than visual inspection suggests. The distal margin of injury cannot be identified electrophysiologically.

**Summary**

Electrodiagnostic studies provide the most objective and quantitative means of evaluating and following patients with peripheral nerve injuries. NCS and needle EMG, together commonly called EMG, allow the localization of disorders of roots or peripheral nerves, measure the type and severity of the injury, and provide prognostic information.

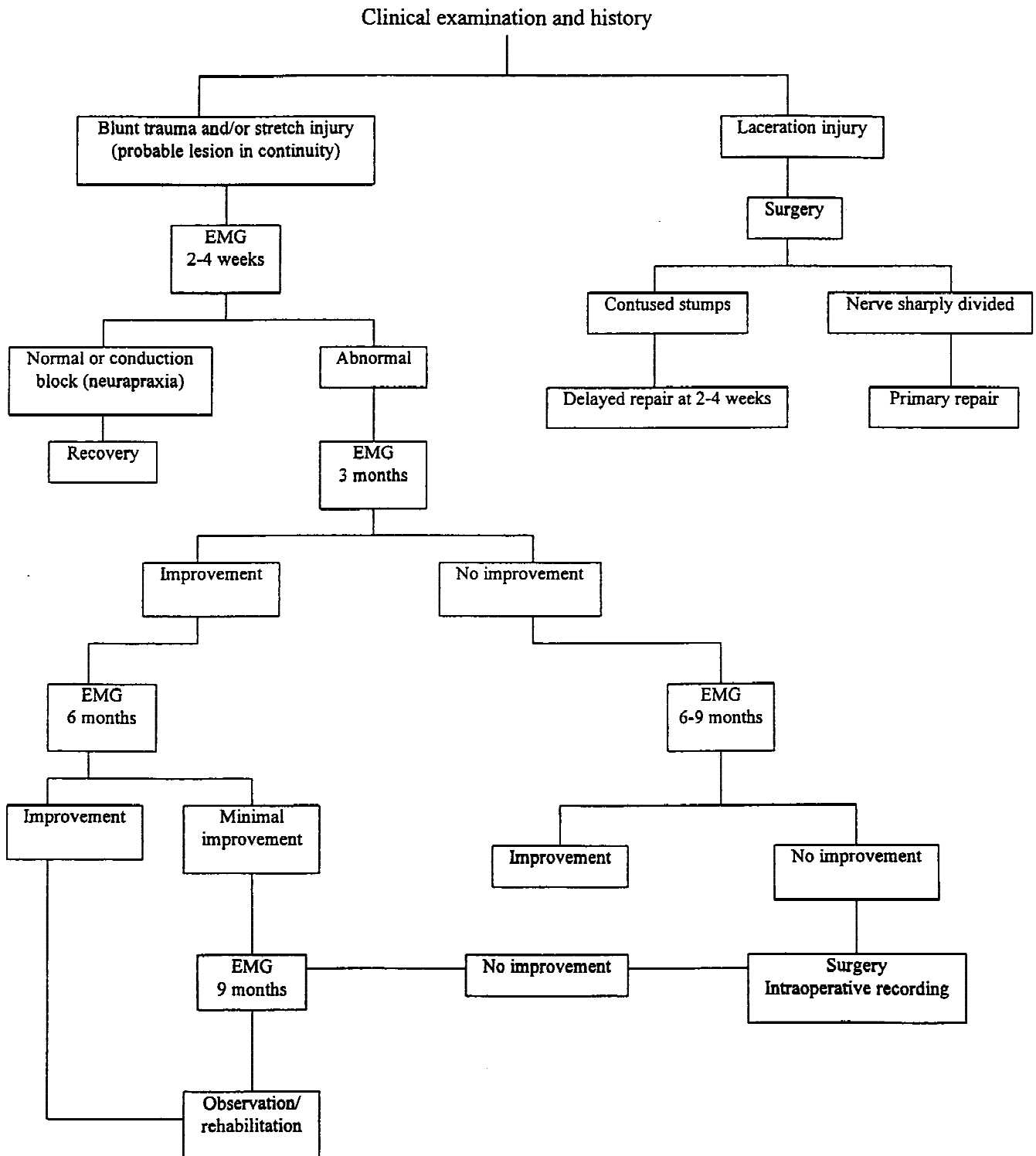


Fig. 3. Use of EMG in the management of severe nerve injuries.

The value and limitations of these studies are best understood in the context of peripheral nerve anatomy and predictable responses to injury and mechanisms of recovery. In addition, it is important to recognize that the electrodiagnostic studies are examiner dependent, particularly in the case of needle EMG.

Timing examinations appropriately reduces the chances of obtaining inconclusive results. There are few situations in which immediate examination after nerve injury is useful. The most informative results will be obtained after 10–14 days. Subsequent examinations are useful to document ongoing recovery, especially when other therapeutic procedures are under consideration. Intraoperative studies may be invaluable in identifying the appropriate circumstance for nerve grafting. NCS and needle EMG, by providing details of the physiologic features of the nerve injury, are extremely useful adjuncts to the clinical neurologic examination and provide important information to help guide therapeutic management.

### References

1. Seddon HJ: Three types of nerve injury. *Brain* 66, 1943.
2. Sunderland S: A classification of peripheral nerve injured producing loss of function. *Brain* 74, 1951.
3. Miller RG: Acute versus chronic compressive neuropathy. *Muscle Nerve* 7:427, 1984.
4. Lundborg G, Dahlin L: The pathophysiology of nerve compression. 4:215, 1992.
5. Selzer ME: Regeneration of peripheral nerve. In: Sumner AJ (ed). *The Physiology of Peripheral Nerve Disease*. Philadelphia: Saunders, p 358, 1980.
6. Schlaepfer WW and Bunge RP: The effects of calcium ion concentration on the degradation of amputated axons in tissue culture. *J Cell Biol* 59:456, 1973.
7. Chaudry V and Cornblath DR: Wallerian degeneration in human nerves: A serial electrophysiologic study. *Muscle Nerve* 15:687, 1992.
8. Trojaborg W: Rate of recovery in motor and sensory fibers of the radial nerve: Clinical and electrophysiologic aspects. *J Neurol Neurosurg Psychiatry* 33:625, 1970.
9. Miller RG: Injury to peripheral motor nerves. *Muscle Nerve* 10:689, 1987.
10. Bird SJ and Brown MJ: Peripheral nerve. In: Dee, et al. (eds). *Principles of Orthopaedic Practice*. New York: McGraw-Hill, p 129, 1997.
11. Sunderland S: *Nerve and Nerve Injuries* (2nd ed). Edinburgh: Churchill Livingstone, 1978.
12. Parry GJ: Electrodiagnostic studies in the evaluation of peripheral nerve and brachial plexus injuries. *Neurol Clin* 10:921, 1992.
13. Hoppel LT and Kline DG: Nerve lesions in continuity. In: Gelberman RH (ed). *Operative Nerve Repair and Reconstruction*. Philadelphia: J. B. Lippincott, p 601, 1991.
14. Dubuisson A and Kline DG: Indication for peripheral nerve and brachial plexus surgery. *Neurol Clin* 10:935, 1992.
15. Kline DG: Timing for exploration of nerve lesions and evaluation of neuroma-in-continuity. *Clin Orthop* 163:42, 1982.