

Results of Treatment of 111 Patients With Nonunion of Femoral Shaft Fractures

P. K. BEREDJIKLIAN, M.D., R. J. NARANJA, M.D., R. B. HEPPENSTALL, M.D., C. T. BRIGHTON, M.D., PH.D., AND
J. L. ESTERHAI, M.D.

Abstract: The purpose of this study is to report our experience with the treatment of femoral shaft fracture nonunion and to define poor prognostic indicators in the treatment of this complication. The records and available radiographs of 111 patients treated for nonunion of the femoral shaft in our institution were retrospectively reviewed. The mean duration of follow-up after establishment of nonunion was 62 months. The following factors were found to have an adverse effect on nonunion healing ($p < 0.05$): (1) advanced patient age; (2) presence of osteomyelitis; (3) presence of synovial pseudarthrosis; (4) duration of nonunion; (5) treatment with flexible intramedullary devices; (6) treatment with compression plating; (7) poor bone stock; (8) malalignment in the anteroposterior plane of more than 10 degrees; and (9) malalignment in the lateral plane of more than 20 degrees.

Introduction

In spite of increased understanding of biomechanics and implant design, nonunion of femoral shaft fractures continues to hinder the treatment of these injuries. This complication presents a difficult treatment challenge for the surgeon and a formidable personal and economic hardship for the patient [8,15]. In most series of femoral fractures treated with modern intramedullary nailing techniques, the incidence of this complication is estimated to be 0.9% [28]. This frequency appears to be on the rise due to advances in trauma care leading to increased survivorship among severely injured patients [28,29].

The treatment of long bone fracture nonunion has been extensively discussed in the orthopaedic literature. The evolution of treatment began with traction and prolonged immobilization as described by Watson-Jones. This was later surpassed by the concept of bony apposition to stimulate primary healing by removing fibrous tissue interposed between the fracture fragments [10,21]. In contrast, Harkins and Phemister [12] contended that this fibrous tissue was necessary for nonunion healing and advocated the use of onlay bone grafts. Other adjuvant methods to stimulate healing have included conventional bone grafting as well as electrical stimulation of osteogenesis in various forms [2,5,6]. In the 1950s, the application of internal fixation in

the form of compression plating as described by Danis and others gained popularity [16,21,22,24]. A few years later, the use of external fixation was introduced as a therapeutic alternative for the treatment of nonunions [1-3,10,25].

Whereas the treatment of femoral shaft fractures has been extensively described in the orthopaedic literature, the data regarding treatment of femoral shaft fracture nonunion are sparse and conflicting. Most of the discussion on long bone nonunions is centered around tibial injuries. Most series available in the current orthopaedic literature comprise a small number of femoral shaft nonunions. The accepted standard of therapy for femoral shaft fracture nonunion invariably includes surgical intervention in the form of closed intramedullary nailing with reaming. More specifically, several authors [4,7,13,14,18,23] recommend removing the present intramedullary nail, reaming the intramedullary canal, and inserting a larger diameter nail. Open autogenous bone grafting in addition to intramedullary reaming has been recommended only in cases of synovial pseudarthrosis or in nonunions with bony defects at the site of injury.

The purpose of this study is to report our experience with the treatment of femoral shaft fracture nonunion and to define poor prognostic indicators in the treatment of this complication.

Materials and Methods

Between 1970 and 1992, 111 patients with nonunion of the shaft of the femur were evaluated and cared for at our institution. For the purposes of this study, nonunion is defined as absence of clinical or radiographic healing 9 months postinjury. The shaft of the femur is defined as the area 5 cm distal to the lesser trochanter proximally and 5 cm proximal to the epicondylar axis distally.

All hospital inpatient and outpatient records were reviewed to determine the following factors: patient age, type of initial injury, description of initial care, number of previous surgeries, treatment for nonunion, complications associated with care, time to union, duration of follow-up, and final status. Available roentgenograms were evaluated to determine bone stock as assessed by the ratio of cortical thickness to shaft width (poor if the ratio was less than one half, adequate if greater than one half), type of nonunion (hypertrophic, oligotrophic, or atrophic), and fracture align-

From the Department of Orthopaedic Surgery, University of Pennsylvania School of Medicine, Philadelphia, PA.
Address correspondence to: P.K. Beredjiklian, M.D., Department of Orthopaedic Surgery, University of Pennsylvania, Philadelphia, PA 19104.

Table 1. Initial treatment of femoral fractures

Treatment	N
Intramedullary nailing	53
Compression plating	27
Skeletal traction	23
Traction followed by casting	4
External fixation	4

Table 2. Treatment modalities for delayed union

Treatment	N
Capacitive coupling (CC)	15
Intramedullary nailing (IM)	6
Compression plating (P)	5
Direct Current (DC)	5
Autogenous bone grafting (BG)	3
External fixation (EX)	1
IM + BG	15
P + BG	5
IM + CC	3
EX + CC	3
P + BG + DC	2
IM + BG + CC	1
EX + DC	1

ment in the anteroposterior (AP) and lateral planes (as measured with a standard goniometer).

Mean patient age at the time of injury was 39.5 years, ranging from 17 to 82 years of age. There were 60 men and 51 women. Fifty-eight nonunions involved the left femur and 53 involved the right. The mechanism of initial injury included motor vehicle accidents (65%, $n = 72$); falls (19%, $n = 21$); osteotomy (6%, $n = 7$); gunshot wounds (3%, $n = 3$); and miscellaneous injuries (7%, $n = 8$). Eighty-nine of the fractures were closed injuries, 15 were open, and seven patients had elective open femoral osteotomies. In the course of treatment, 34 (31%) nonunions developed culture-proven osteomyelitis and 18 (16%) developed synovial pseudarthroses as determined by either biopsy or bone scan.

Patient treatment was temporally classified into three separate categories: initial treatment at the time of femoral fracture; treatment of the delayed union (i.e., surgical intervention performed after the initial fracture treatment but before the establishment of nonunion defined at 9 months postinjury); and treatment of the established nonunion. Initial treatment of the femoral fracture included intramedullary nailing (48%, $n = 53$); compression plating (24%, $n = 27$); traction (20%, $n = 23$); traction followed by casting or cast bracing (3%, $n = 4$); and external fixation (3%, $n = 4$) (Table 1).

Treatment of delayed union in our patient population was varied. Fifty-nine (53%) of the patients in the study were treated either surgically (a total of 50 surgical procedures) or with capacitive coupling alone (12 patients) as described in Table 2. Six of these patients went on to heal the femoral nonunion without any further intervention.

Table 3. Ineffective treatment modalities for nonunion

Treatment	N
Capacitive coupling (CC)	20
Intramedullary nailing (IM)	7
Compression plating (P)	4
Direct Current (DC)	20
Autogenous bone grafting (BG)	15
External fixation (EX)	3
IM + BG	14
P + BG	8
IM + CC	1
P + CC	2
P + DC	1
EX + BG	1
P + BG + CC	2
IM + BG + CC	2
BG + CC	2

Table 4. Effective treatment modalities for nonunion

Treatment	N
Capacitive coupling (CC)	12
Intramedullary nailing (IM)	4
Compression plating (P)	1
Direct Current (DC)	11
Autogenous bone grafting (BG)	6
IM + BG	13
P + BG	1
P + DC	1
IM + BG + CC	4
BG + CC	1

Treatment of the established nonunion was also varied and included several forms of internal and external fixation, as well as adjunctive treatment with bone grafting and/or electrical stimulation of osteogenesis in the form of capacitive coupling or direct current. Treatment modalities were considered failures if (1) the femur remained ununited during the available documented follow-up after the intervention in question or if (2) another treatment modality was instituted during the time of recorded follow-up, in all cases due to an absence of bony healing. A total of 82 failed surgical interventions were recorded, with an additional 20 patients undergoing capacitive coupling (Table 3). Treatment modalities were considered successful if bony healing was achieved following the intervention in question. Healing was achieved in these patients with a total of 42 surgical interventions with an additional 12 patients undergoing capacitive coupling (Table 4).

Statistical analysis was performed using the Student's t test for numeric data and chi square analysis for nonparametric data.

Results

The mean time from fracture to care at our institution was 24.5 months (range 0–144) and the patients had undergone




Fig. 1. Nonunion treatment with intramedullary nails.

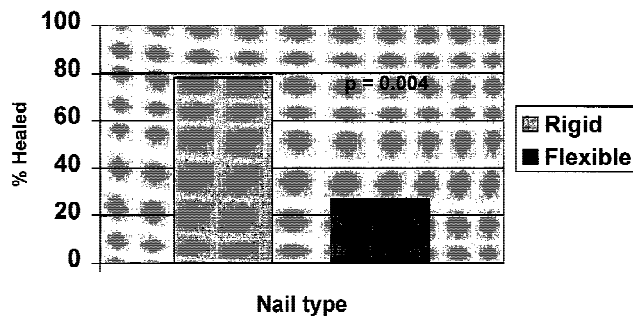


Fig. 2. Nail type versus healing.

an average of two surgical procedures (range 0–8) prior to presentation. The mean duration of follow-up after establishment of nonunion was 62 months.

Fifty-five (49%) of the nonunions healed and 56 (51%) did not heal as determined by the available follow-up. Data analysis revealed a significant difference in the average age of those patients who healed (35.9 years, range 17–82) versus those who did not (42.9 years, range 18–81) ($p = 0.026$). The presence of osteomyelitis adversely influenced healing, as only 10 of 34 (29.4%) infected nonunions healed ($p = 0.007$). As expected, open fractures resulted in a significantly higher incidence of infected nonunions (11 of 23, 48%; $p = 0.021$). In addition, only 4 of 18 (22.2%) patients with synovial pseudarthroses went on to heal their femoral nonunion ($p = 0.013$).

The mode of initial treatment of the femoral shaft fracture did not significantly impact the result of nonunion treatment. However, statistically significant differences in healing rates were found between different treatment modalities for established nonunions. Intramedullary rodding with reaming (with and without open adjuvant bone grafting and/or electrical stimulation of osteogenesis) was the most successful mode of therapy for the established nonunion. Of the patients treated in this fashion, 21 of 45 (47%) went on to heal their nonunion ($p = 0.031$) (Fig. 1). Furthermore, in 34 of 45 patients treated with intramedullary nails, we were able to assess the type of device used (rigid [e.g., Kuntschner or Russell-Taylor type nails] versus flexible [e.g., Enders or Rush rods]). Notably, patients treated with rigid devices had a significantly higher rate of nonunion healing (18 of 23) than those treated with flexible nails (3 of 11; $p = 0.004$) (Fig. 2). It is unclear from our data whether the addition of bone grafting and/or electrical stimulation of osteogenesis as adjuvants to intramedullary rodding improved the outcome of treatment.

In contrast, compression plating of the established nonunion (with and without adjuvant bone grafting and/or electrical stimulation of osteogenesis) generally resulted in a poor outcome. In comparison to all other treatment modalities, only 3 of 20 (15%) patients treated in this fashion went on to heal their nonunion ($p = 0.044$; Fig. 3). It is unclear from our data whether the addition of bone grafting and/or electrical stimulation of osteogenesis as adjuvants to plating improved the outcome of treatment.

We found no statistically significant differences regarding other types of treatment and nonunion healing. Neither capacitive coupling alone (12 of 33 healed versus 43 of 130 healed for all other treatment types, $p = 0.72$) nor direct current alone (11 of 31 healed versus 44 of 132 healed for all other treatment types, $p = 0.82$) revealed differences in healing rates. Bone grafting alone also proved no more effective than other types of treatment (6 of 21 healed versus 49 of 142 healed for all other treatment types, $p = 0.59$).

Radiographic analysis revealed that significant predictors of poor outcome included bone stock and malalignment in the AP and lateral planes.

Bone stock

Only 4 of 26 patients determined to have poor bone stock by the earliest available radiographs obtained after the establishment of the nonunion went on to heal. In contrast, 23 of 50 patients with adequate bone stock healed their nonunions ($p = 0.008$).

Malalignment of the fracture in the AP plane greater than 10 degrees

Twenty-five of 51 (49%) patients with adequate alignment in the AP plane went on to heal, whereas 19 of 25 (76%) patients with deformity of more than 10 degrees in this plane did not heal their nonunions ($p = 0.03$).

Malalignment of the fracture ends in the lateral plane greater than 20 degrees

Thirty-one of 57 (54%) patients with adequate alignment in the lateral plane went on to heal, whereas 15 of 19 (79%) patients with deformity of more than 20 degrees in this plane did not heal their nonunions ($p = 0.011$).

Notably, nonunion type (e.g., hypertrophic versus atrophic) did not yield significant differences in healing rates.

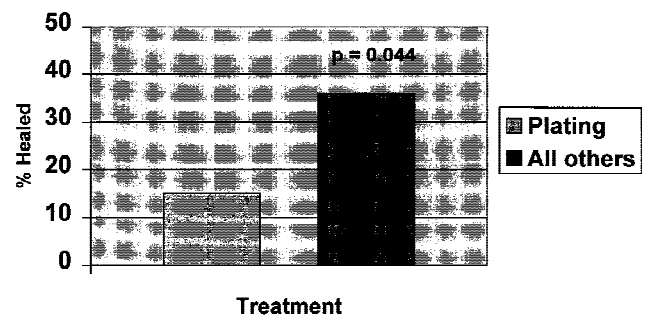


Fig. 3. Nonunion treatment with compression plating.

Finally, the presence of implant failure or frank loosening also did not reliably predict poor outcome.

Three patients in this study group underwent above the knee amputations for treatment of a recalcitrant nonunion. All of the significant clinical and radiographic predictors of outcome are outlined in Table 5.

Discussion

Historically, nonunion of long bone fractures has been the subject of intensive study in the orthopaedic literature. This fact undoubtedly stems not only from the inherent difficulty in treating this complication, but also from the enormous physical and psychological demands placed on the patient. Of 602 long bone nonunions, Connolly [8] estimated that 62% were located in the tibia, with only 23% occurring in the femur. The higher incidence of tibial nonunion may explain why most of the discussion concerning treatment has focused on tibial injuries. Nevertheless, femoral nonunion remains a relatively common occurrence with catastrophic consequences.

The existing orthopaedic literature is lacking in an analysis of a large series of femoral shaft nonunions. However, careful review of the existing literature regarding femoral nonunion does provide some answers regarding management. Taylor [26] advocated the use of two slotted plates at 90 degrees to each other with cortical bone graft for the definitive treatment of femoral nonunion. A few years later, Brav [4] advocated the use of open intramedullary nailing with bone grafting as the procedure of choice in the treatment of femoral shaft nonunion. Rigid fixation and early rehabilitation were noted as the key factors in the success of this procedure. Klemm [19], Kostuik and Harrington [20], and Varma and Rao [27] expanded the indications of intramedullary nailing to include infected nonunions of the femoral shaft. They found this method of treatment superior to compression plating for nonunion healing. In the early 1980s, Brighton et al. [5] and Bassett et al. [3] added electrical stimulation of osteogenesis to the treatment armamentarium.

The advent of improved implant design has helped achieve excellent results treating femoral shaft delayed and nonunions with a success rate approaching 100%. Webb et al. [28] reported a total of 44 nonunions of the femur, all treated with reamed intramedullary nails. Nonunion was

defined as an ununited fracture lasting longer than 1 year. It is unclear, however, how many of these injuries involved the femoral shaft. The authors do not state the average length of nonunion duration nor the number of surgical procedures that patients had undergone prior to the assumption of care by the authors.

Our data highlight significant risk factors in the treatment of femoral shaft nonunions. Advanced patient age, the number of surgical procedures, and the duration of nonunion all were demographic factors inversely proportional in treatment success rates. The first two factors likely relate to the physiologic capacity of patients to heal their nonunion. The orthopaedic surgeon should be aware of the patient's general medical condition and nutritional status, as these factors may be requisite in successful nonunion treatment.

Other factors related to poor prognosis include the presence of osteomyelitis and synovial pseudarthrosis at the nonunion site. The nonunions complicated by osteomyelitis probably represent a subgroup of more severe injuries than the rest of the group. Open fractures, injuries resulting from high energy trauma, and fractures occurring in debilitated hosts are more likely to develop infection and predispose patients to a poor outcome. Synovial pseudarthroses are thought to result from gross motion at the fracture site due to inadequate immobilization [15]. It is believed that poor fixation results in metaplasia of the lining tissue at the fracture site consisting of fibroblasts and histiocytes, tissue comparable to that present in synovial joints. Given the poor healing rates in these cases, it is clear that this environment is not conducive to fracture healing. Our data support this assertion.

In a similar study, Brighton et al. [6] identified risk factors adversely associated with the treatment of tibial nonunion. Using logistic regression analysis, the authors reviewed the treatment results of 271 tibial fracture nonunions with an average follow-up of 23.5 months. In this group of patients, the authors identified duration of nonunion, prior bone graft surgery, prior electrical treatment, open fracture, osteomyelitis, comminuted or oblique fracture, and atrophic nonunion as poor prognostic indicators in the treatment of tibial nonunion.

With regard to the radiographic analysis in our study, the presence of poor bone stock and malalignment in the AP and lateral planes presaged a precarious outcome. The evaluation of bone stock from plain radiographs is technique dependent and inexact. There exist no reproducible objective parameters for this determination. In fact, it is believed that between 30–50% of bone mass must be lost before any degree of osteopenia becomes apparent in plain films. Recently, the advent of dual energy x-ray absorptiometry (DEXA) scanning has provided an accurate and reproducible method of quantitating bone [11]. This modality was not available during the treatment of patients in this study. Comparing the cortical width to the width of the shaft does provide a rough guideline for the determination of bone stock. These measurements significantly correlated with nonunion healing potential.

The best results were achieved with rigid intramedullary

Table 5. Clinical and radiographic predictors of poor outcome ($p < 0.05$)

Advanced patient age
Presence of osteomyelitis
Presence of Synovial Pseudarthrosis
Duration of nonunion
Treatment with flexible intramedullary devices
Treatment with compression plating
Poor bone stock
Malalignment in the anteroposterior plane > 10 degrees
Malalignment in the lateral plane > 20 degrees

nail fixation of the established nonunion. Court-Brown et al. [9] hypothesized that intramedullary nailing with reaming may stimulate bony union in tibial injuries for the following reasons: (1) increased stability, (2) autografting of osteoinductive reaming products, and (3) increased periosteal new bone formation and blood flow. It is interesting to note that the nonunions in our study treated with flexible intramedullary devices had significantly lower healing rates when compared to stiff nails. These data highlight the importance of stability as it relates to rigid fixation and the potential osteoinductive properties of the reaming process in the management of femoral shaft nonunion.

In contrast, compression plating of the injuries under study yielded poor results. Several factors may account for this finding. First, application of the plate necessitates the devascularization of a segment of bone at the nonunion site. Damage to the soft tissues as well as disruption of the periosteal blood supply at the site of injury may inhibit the healing potential of the nonunion. Second, a single plate is biomechanically inferior to an intramedullary rod in regard to the torsion and bending characteristics [14]. It is possible that compression plating may have a role in the treatment of proximal or distal femoral nonunion. However, it appears as if its use in femoral shaft nonunions is not tenable.

At the time of treatment of the patients in this study, our institution was a large referral center for the treatment of long bone nonunion. Thus, the data presented in this study may describe a group of nonunions recalcitrant in nature, those that were not responsive to initial treatment by the primary orthopaedist. This fact may explain the marginal success rate in treating the nonunions reported here. In addition, most of the implants used in this study reflect technology used as long as 10 to 20 years ago, and thus our results do not reflect the benefits gained from advances in implant design. The development of newer implants, as well as the use of osteoinductive substances such as bone morphogenetic protein (BMP), may substantially improve the results of treatment of femoral shaft fracture nonunion [17].

References

- Alonso JG and Hughes JL: External fixation of femoral fractures. *Clin Orthop* 241:83-88, 1989.
- Barquet A, Silva R, Massafiero J, et al.: The AO tubular external fixator in the treatment of open fractures and infected non-unions of the shaft of the femur. *Injury* 19:415-420, 1988.
- Bassett CA, Mitchell SN, Schink MM: Treatment of therapeutically resistant non-unions with bone grafts and pulsing electromagnetic fields. *J Bone Joint Surg* 64A:1214-1220, 1982.
- Brav EA: The use of intramedullary nailing for nonunion of the femur. *Clin Orthop* 60:69-75, 1968.
- Brighton CT, Friedenberz ZB, Esterhai JL, et al.: Treatment of nonunion with constant direct current. *J Bone Joint Surg* 63A:2-13, 1981.
- Brighton CT, Shaman P, Heppenstall RB, et al.: Tibial nonunion treated with direct current, capacitive coupling, or bone graft. *Clin Orthop* 321:223-234, 1995.
- Christensen NO: Kuntscher intramedullary reaming and nail fixation for non-union of fracture of the femur and the tibia. *J Bone Joint Surg* 55B:312-318, 1973.
- Connolly JF: Common avoidable problems in nonunions. *Clin Orthop* 194:226-235, 1985.
- Court-Brown CM, Keating JF, Christie J, et al.: Exchange intramedullary nailing. *J Bone Joint Surg* 77B:407-???, ????
- Fellander M: Treatment of fractures and pseudarthroses of the long bones by Hoffmann's transfixation method (osteotaxis). *Acta Orthop Scand* 33:133-150, 1963.
- Genant HK, et al.: Appropriate use of bone densitometry. *Radiology* 170:817-822, 1991.
- Harkins HN and Plemister DB: Simplified technique of onlay grafts for all ununited fractures in acceptable position. *JAMA* 109:1501-1510, 1937.
- Harper MC: Ununited fractures of the femur stabilized with a fluted rod. *Clin Orthop* 190:273-278, 1984.
- Heiple KG, Figgie HE, Lacey SH, et al.: Femoral shaft nonunion treated by a fluted intramedullary rod. *Clin Orthop* 194:218-225, 1984.
- Heppenstall RB, Brighton CT, Esterhai JL, et al.: Synovial pseudarthrosis: A clinical, roentgenographic, scintigraphic, and pathologic study. *J Trauma* 27:463-470, 1987.
- Johnson EE: Custom titanium plating for failed nonunion or delayed internal fixation of femoral fractures. *Clin Orthop* 234:195-203, 1988.
- Johnson EE, Urist MR, Finerman GA: Bone morphogenetic protein augmentation grafting of resistant femoral nonunions. A preliminary report. *Clin Orthop* 230:257-265, 1988.
- Kempf I, Grosse A, Rigaut P: The treatment of noninfected pseudarthrosis of the femur and tibia with locked intramedullary nailing. *Clin Orthop* 212:142-154, 1986.
- Klemm KW: Treatment of infected pseudarthrosis of the femur and tibia with an interlocking nail. *Clin Orthop* 212:174-181, 1986.
- Kostuik JP and Harrington IJ: Treatment of infected un-united femoral shaft fractures. *Clin Orthop* 108:90-94, 1975.
- Muller ME: Treatment of nonunion by compression. *Clin Orthop* 43:83-91, 1966.
- Muller ME and Thomas RJ: Treatment of non-union in fractures of long bones. *Clin Orthop* 138:141-153, 1979.
- Oh I, Nahigian SH, Rascher JJ, et al.: Closed intramedullary nailing for ununited femoral shaft fractures. *Clin Orthop* 106:206-215, 1986.
- Rosen H: Compression treatment of long bone pseudarthroses. *Clin Orthop* 138:154-166, 1979.
- Slatys P and Paavolainen P: External fixation of infected non-unions of the femur. *Injury* 16:599-604, 1985.
- Taylor LW: Principles of treatment of fractures and non-union of the shaft of the femur. *J Bone Joint Surg* 45A:191-198, 1963.
- Varma BP and Rao YP: An evaluation of the results of medullary nailing in the treatment of infected diaphyseal fractures. *Clin Orthop* 100:151-159, 1974.
- Webb LX, Winkquist RA, Hansen ST: Intramedullary nailing and reaming for delayed union or nonunion of the femoral shaft: A report of 105 consecutive cases. *Clin Orthop* 212:133-141, 1986.
- Winkquist RA, Hansen ST, Clawson DK: Closed intramedullary nailing of femoral fractures: A report of five hundred and twenty cases. *J Bone Joint Surg* 66A:529-539, 1984.