



Postoperative Aspirin Use is Associated with Delayed Progression of Radiographic Healing in Tibial Fractures Treated with Internal Fixation

Derek G. Dombroski, MD¹

John MacKenzie, MD²

Li-Xing Man, MD³

John L. Esterhai, MD¹

Jaimo Ahn, MD¹

1 Department of Orthopaedic Surgery, University of Pennsylvania, Philadelphia, PA

2 Department of Radiology, The Children's Hospital of Philadelphia, Philadelphia, PA

3 Department of Otolaryngology, University of Pittsburgh, Pittsburgh, PA

The clinical role of prostaglandins in fracture healing has yet to be fully elucidated. Data from animal models have shown that some nonsteroidal anti-inflammatory medications (NSAIDs) inhibit fracture healing. However, a clear clinical association between prostaglandin inhibition and delayed fracture healing has not been established. Specifically, the effects of acetylsalicylic acid (ASA) on fracture healing are unknown. The goal of our study was to test the relationship between postoperative ASA use and progression of radiographic healing of tibial fractures acutely treated with internal fixation. Thirty-five radiographs of consecutive tibial shaft fractures (OTA/AO 42) treated with intramedullary fixation were prospectively reviewed and graded for healing. Least square regression modeling was used to assess if an effect of postoperative ASA use on radiographic healing grade over time was present. Patients with and without ASA treatment had similar demographic and injury parameters. Our data show that ASA treatment had a statistically significant effect on fracture healing that decreased radiographic callus formation when compared to patients not receiving ASA postoperatively. Progression of time increased radiographic grade. Age was not associated with healing progression. Our data suggest postoperative administration of ASA delays progression of radiographic fracture healing in tibial fractures treated with intramedullary fixation. This data supports the notion that prostaglandin inhibition may have a negative effect on proper bony healing. Our results stress the importance of further study regarding the role of prostaglandin inhibition on clinical fracture healing.

Timely healing of fractures serves to minimize the burden of disease on patients and the healthcare system. Delays in fracture union and nonunion pose a significant impact on both the patient and the healthcare system. Estimates of the treatment cost of a tibial fracture nonunion exceed \$25,000¹. This estimate also assumes a best-case scenario where successful healing follows the initial treatment plan. Factors that can slow or stop fracture healing present a potential role for intervention where delays in fracture healing may be removed or minimized.

One such factor that may delay fracture healing is non-steroidal anti-inflammatory drugs (NSAIDs). NSAIDs are oral medications that act by inhibition of cyclooxygenases (COX) and therefore downregulate prostaglandin (PG) synthesis. While NSAIDs have many roles in patient care, including antipyretic, analgesic, thromboembolic prophylaxis, and protective effects against ischemic cardiac events, they may possess a deleterious effect on fracture healing.

Experimental models have shown a negative relationship between COX inhibition and bone healing²⁻⁶. Although a few studies have suggested a similar relationship in humans⁷⁻⁹, a clear association between clinical inhibition of PG synthesis and delayed fracture healing has not been established. Acetylsalicylic acid (ASA) or aspirin, is one such NSAID that inhibits both isoforms of COX (COX-1 and COX-2) and is commonly used in trauma patients.

The effect of ASA on bone healing remains unknown. We examined the relationship between postoperative ASA treatment and healing of intramedullary fixed tibial fractures over time. Our null hypothesis was that the use of ASA would not delay radiographic progression of healing in these injuries.

Materials and Methods

A retrospective review of all diaphyseal tibial fractures (OTA/AO 42) treated with intramedullary fixation at our single institution between January 2004 and December 2005 was performed. Our inclusion criteria were complete electronic medication list available, no significant ipsilateral limb injury, ability to ambulate and participate in therapy after surgery, closed injury or open but amenable to acute definitive fixation, and radiographic follow-up available. Data for variables of interest were extracted from a final cohort of 35 patients (19 received ASA after surgery, 16 did not).

A retrospective chart review extracted secondary variables (age, open/closed, blood transfusions received, days in hospital, discharged home, cardiac co-morbidity, distribution of OTA A/B/C types, nail diameter, tobacco use, final follow-up time) of all patients. Radiographs were then masked, prospectively and independently analyzed, and scored based on a scoring scale we created from 0-4. Our new scale consisted of five units (0-4). Zero was given to acute fractures; 1

Corresponding Author:

Derek G. Dombroski, MD
Department of Orthopaedic Surgery
University of Pennsylvania
3400 Spruce Street, 2 Silverstein
Philadelphia, PA 19104
Derek.Dombroski@uphs.upenn.edu

Radiographic Grading of Fracture Healing

- 0: acute fracture
- 1: periosteal or cortical thickening/blurring
- 2: immature or thin callus
- 3: maturing callus, fracture lucency present
- 4: healed, remodeled cortices

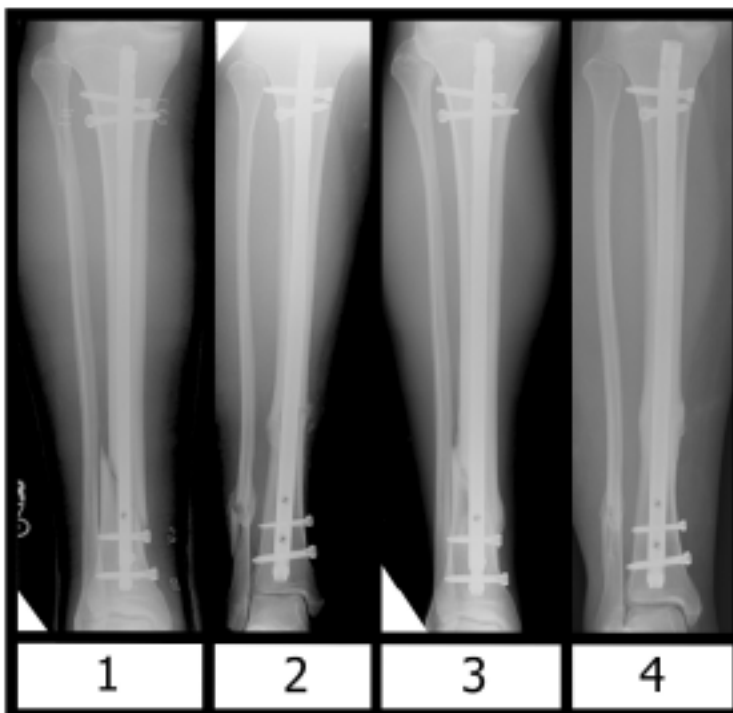


Figure 1. Radiographic grading of fracture healing was independently graded based on a 0 to 4 scale in a blinded fashion by a musculoskeletal radiologist.

to periosteal/cortical thickening/blurring; 2 for fractures with immature or thin callus; 3 for maturing callus with fracture lucency present; 4 for healed, remodeled cortices. This fracture callus scoring system was devised in coordination with a musculoskeletal-trained radiologist.

The ASA and no ASA cohorts were compared for secondary variables. Least squares regression was used to model the effect of postoperative ASA on radiographic healing over time (time 0 = postoperative x-ray) by comparing the two groups. Fisher's exact test was used to compare categorical variables between the two groups. Statistical analyses were performed using a commercial statistics package (STATA; College Station, TX), and significance was set at $p=0.05$.

Results

The average age of the patient was 38 years of age (range, 18 to 77). Motor vehicle crash was the most common injury mechanism ($n=17$). Seventeen of the 35 fractures were OTA type A fractures. Twelve of the fractures were open. All patients were treated with reamed, statically locked intramedullary nailing within 72 hours of injury. Mean nail diameter was 10.1 mm. Patients were discharged an average of 7.5 days after injury with 21 receiving further therapy at an in-patient rehabilitation center. Average final follow-up time was 23 weeks (range, 4 to 52) after surgery.

The values of secondary variables were not significantly different between the two cohorts. Open fractures, OTA type, nail diameter, tobacco use, insulin-dependent diabetes, blood transfusions, hospital stay, discharge disposition, number of x-ray evaluations, or final follow up time between the ASA and non-ASA cohorts were not significant ($p>0.05$). The no ASA

group had more patients involved in a MVC (11 of 15 versus 6 of 18, $p=0.025$).

The fracture healing scores by the radiologist showed high intra-observer ($r=0.915$) and intra-class reliability ($r=0.914$). The relationship between radiographic score and time is shown graphically in Figure 2. Regression modeling and comparison showed that the use of ASA had an average decreased radiographic score of 0.34. This decrease in healing progression was statistically significant (95% CI 0.06, 0.62, $p=0.02$) versus no ASA over time. As expected, progression of time increased radiographic grade (0.07 per week; $p<0.01$).

Discussion

The role of NSAIDs, and specifically ASA, in fracture healing remains to be fully elucidated. Prospective animal study data is equivocal in outcomes, as some studies fail to show any effect of NSAIDs on fracture healing^{10, 11}. However, the majority of animal data supports the hypothesis that NSAIDs inhibit fracture healing^{2, 3, 12, 13}. These studies are difficult to interpret as a number of different variables including specific NSAID used, animal model, fracture model, and measured outcomes are different among these experimental models.

The data from human studies is sparse and conflicting as well. Two retrospective studies in humans have shown an association of NSAIDs with delayed healing in humeral and femoral fractures^{1, 8}. A randomized controlled study looking at bone mineral density and NSAID use in distal radius fractures failed to associate NSAID use with delayed or nonunions⁷. Furthermore, none of these studies looked at the role of ASA in particular.

ASA is a medication commonly used for a variety of indications in trauma patients and knowledge of its role in

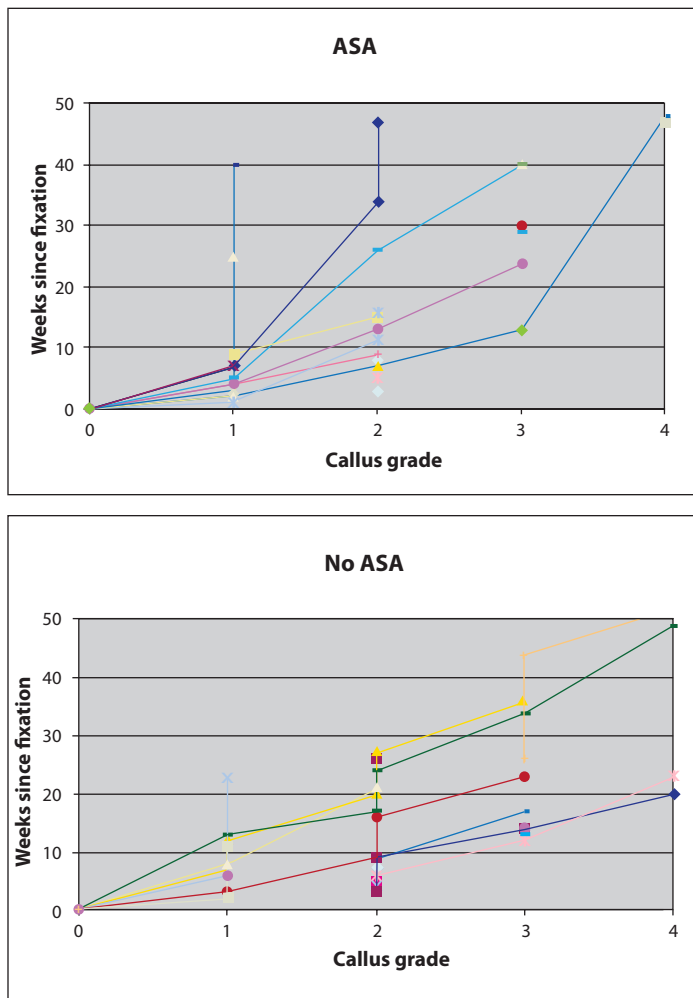


Figure 2. Fracture callus grade as a function of time since fixation was plotted as a function of time. Each point represents a grading event based on a set of follow-up x-rays. Each line represents a single patient.

fracture healing is important. In the setting of an acute tibial shaft fracture treated with intramedullary fixation, our data support the hypothesis that ASA use is associated with delayed radiographic healing. This is the first study that we are aware of to investigate and find such a relationship.

There are some important limitations to our study. One, it is retrospective in nature and not randomized. Therefore, our study has an unknown number of potential confounders and biases. We attempted to surmount this deficit by setting our hypothesis and variables *a priori* (to limit data mining), comparing a number of variables between our cohorts (to show that our cohorts were otherwise similar with a low likelihood of significant confounders), and analyzing our x-rays prospectively by an independent expert.

Second, follow-up intervals and times showed high variability within cohorts. This variability made it difficult to treat time as a truly parametric variable. Indeed, the use of

time as a variable in any such study is difficult, as typically selected intervals for follow-up cannot capture the full spectrum of change in healing (*i.e.* if an x-ray at time A showed one bridged cortex and time B showed four, it is unclear when the other cortices united). However, after consulting multiple statisticians, a better model could not be constructed.

Third, a validated fracture healing grading system does not exist in the literature. The evaluation of fracture healing using x-rays is of unknown objectivity as it has not been published. Therefore, we used a simple practical system that showed good reliability. Moving forward, a clinically-validated grading system will need to be developed.

In summary, our data suggest that postoperative administration of ASA interferes with the progression of radiographic fracture healing in tibia fractures treated with intramedullary fixation and supports the hypothesis that clinical inhibition of prostaglandins may inhibit proper bony healing. Our results stress the importance of further study regarding the role of prostaglandin inhibition on fracture healing in humans.

References

1. Kanakaris NK, Giannoudis PV. The health economics of the treatment of long-bone non-unions. *Injury*. 2007 May;38 Suppl 2:S77-84.
2. Dimmen S, Nordsletten L, Madsen JE. Parecoxib and indomethacin delay early fracture healing: a study in rats. *Clin Orthop Relat Res*. 2009 Aug;467(8):1992-9.
3. Murnaghan M, Li G, Marsh DR. Nonsteroidal anti-inflammatory drug-induced fracture nonunion: an inhibition of angiogenesis? *J Bone Joint Surg Am*. 2006 Nov;88 Suppl 3:140-7.
4. Naik AA, Xie C, Zuscik MJ, Kingsley P, Schwarz EM, Awad H, et al. Reduced COX-2 expression in aged mice is associated with impaired fracture healing. *J Bone Miner Res*. 2009 Feb;24(2):251-64.
5. Yoshida K, Oida H, Kobayashi T, Maruyama T, Tanaka M, Katayama T, et al. Stimulation of bone formation and prevention of bone loss by prostaglandin E EP4 receptor activation. *Proc Natl Acad Sci U S A*. 2002 Apr 2;99(7):4580-5.
6. Zhang X, Schwarz EM, Young DA, Puzas JE, Rosier RN, O'Keefe RJ. Cyclooxygenase-2 regulates mesenchymal cell differentiation into the osteoblast lineage and is critically involved in bone repair. *J Clin Invest*. 2002 Jun;109(11):1405-15.
7. Adolphson P, Abbaszadegan H, Jonsson U, Dalen N, Sjöberg HE, Kalen S. No effects of piroxicam on osteopenia and recovery after Colles' fracture. A randomized, double-blind, placebo-controlled, prospective trial. *Arch Orthop Trauma Surg*. 1993;112(3):127-30.
8. Bhattacharyya T, Levin R, Vrahas MS, Solomon DH. Nonsteroidal antiinflammatory drugs and nonunion of humeral shaft fractures. *Arthritis Rheum*. 2005 Jun 15;53(3):364-7.
9. Giannoudis PV, MacDonald DA, Matthews SJ, Smith RM, Furlong AJ, De Boer P. Nonunion of the femoral diaphysis. The influence of reaming and non-steroidal anti-inflammatory drugs. *J Bone Joint Surg Br*. 2000 Jul;82(5):655-8.
10. Brown KM, Saunders MM, Kirsch T, Donahue HJ, Reid JS. Effect of COX-2-specific inhibition on fracture-healing in the rat femur. *J Bone Joint Surg Am*. 2004 Jan;86-A(1):116-23.
11. Mullis BH, Copland ST, Weinhold PS, Miclau T, Lester GE, Bos GD. Effect of COX-2 inhibitors and non-steroidal anti-inflammatory drugs on a mouse fracture model. *Injury*. 2006 Sep;37(9):827-37.
12. Bo J, Sudmann E, Marton PF. Effect of indomethacin on fracture healing in rats. *Acta Orthop Scand*. 1976 Dec;47(6):588-99.
13. Allen HL, Wase A, Bear WT. Indomethacin and aspirin: effect of nonsteroidal anti-inflammatory agents on the rate of fracture repair in the rat. *Acta Orthop Scand*. 1980 Aug;51(4):595-600.