

# Short Proximal Femur “Hip Salvage” Endoprosthetic Reconstruction for Children with Bone Sarcomas: A Report of Two Cases

Juan Pretell-Mazzini, MD<sup>1</sup>

Lauren Tomlinson, BS<sup>2</sup>

John P. Dormans, MD<sup>3</sup>

<sup>1</sup> Doce de Octubre Hospital, Pediatric unit  
Avda. De Córdoba s/n  
Madrid, Spain, 28041

<sup>2</sup> The Children's Hospital of Philadelphia  
34th and Civic Center Boulevard 2nd floor  
Wood Building  
Philadelphia, PA, 19104-4399

<sup>3</sup> The Children's Hospital of Philadelphia  
University of Pennsylvania School of Medicine  
34th and Civic Center Boulevard 2nd floor  
Wood Building  
Philadelphia, PA, 19104-4399

In up to 90% of cases, limb salvage surgery is the preferred treatment for bone sarcomas affecting skeletally immature children. Extensive involvement of the femur may be seen in some cases, necessitating a total femoral reconstruction. Little is known about the effects of this treatment on the developing acetabulum, however. If possible, a technique that allows for preservation of the hip joint in young children should be used. In this report, we describe two cases of extensive femoral involvement due to osteosarcoma in very young children in which an endoprosthetic reconstruction with an expandable endoprosthesis associated with an intertrochanteric osteotomy was performed as an alternative treatment to reconstruction with a total femoral endoprosthesis. To the best of our knowledge, this is the first report describing an approach aimed to preserve the native hip so as to maintain normal development of the acetabula and near normal function of the abductor muscles. .

**Key words:** expandable endoprosthesis, osteosarcoma, intertrochanteric osteotomy, acetabular growth arrest, abductor muscle weakness.

## Introduction

Historically, the reconstruction options after resection of malignant bone tumors in the lower limb of skeletally immature patients were limited to amputation and biological reconstruction, although rotationplasty has also been described<sup>1</sup>. Limb salvage surgery (LSS) is now the preferred treatment at most institutions, with approximately 90% of patients presenting as suitable candidates<sup>2-4</sup>.

The femur is the most common site for primary malignant tumors of bone in children<sup>2</sup>; however, hip replacement by means of a proximal femoral or a total femur reconstruction is rarely required.

When a massive intramedullary extension of a diaphyseal sarcoma is present, total femoral reconstruction is recommended<sup>5-7</sup>. This reconstruction involves the replacement of both the knee and hip joint. Good functional outcomes have been reported with regards to the knee<sup>5, 6, 8, 9</sup>; however, few sources address hip related functional outcomes following this type of reconstruction in the skeletally immature. Furthermore, little is known about the development of the acetabulum without a natural femoral head to mold it<sup>10</sup>. Irregular development can result in hip dysplasia and possible superior and lateral migration (subluxation) of the joint. For this reason, maintaining the hip joint may be crucial in ensuring better clinical outcomes.

The use of a bipolar hemiarthroplasty in children between six and fourteen years old following tumor resection has been reported to lead to superior and lateral migration of the femoral head, resulting in a 20% revision rate by five years<sup>11</sup>. In another study in patients over 11 years old, the revision rate was 25%, increasing

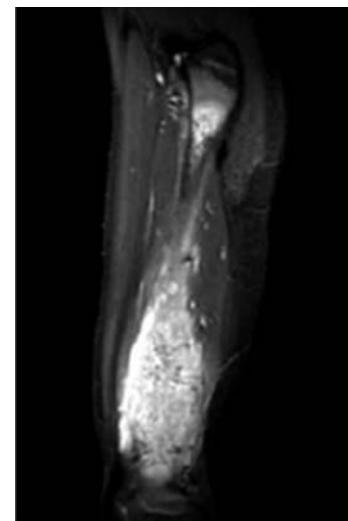
up to 75 % in younger patients in a ten year period of time<sup>10</sup>.

We report two cases in which a unique approach was used to preserve the native hip joint in patients with skip lesions as well as extensive involvement of the femur.

## Case Reports

### Case 1

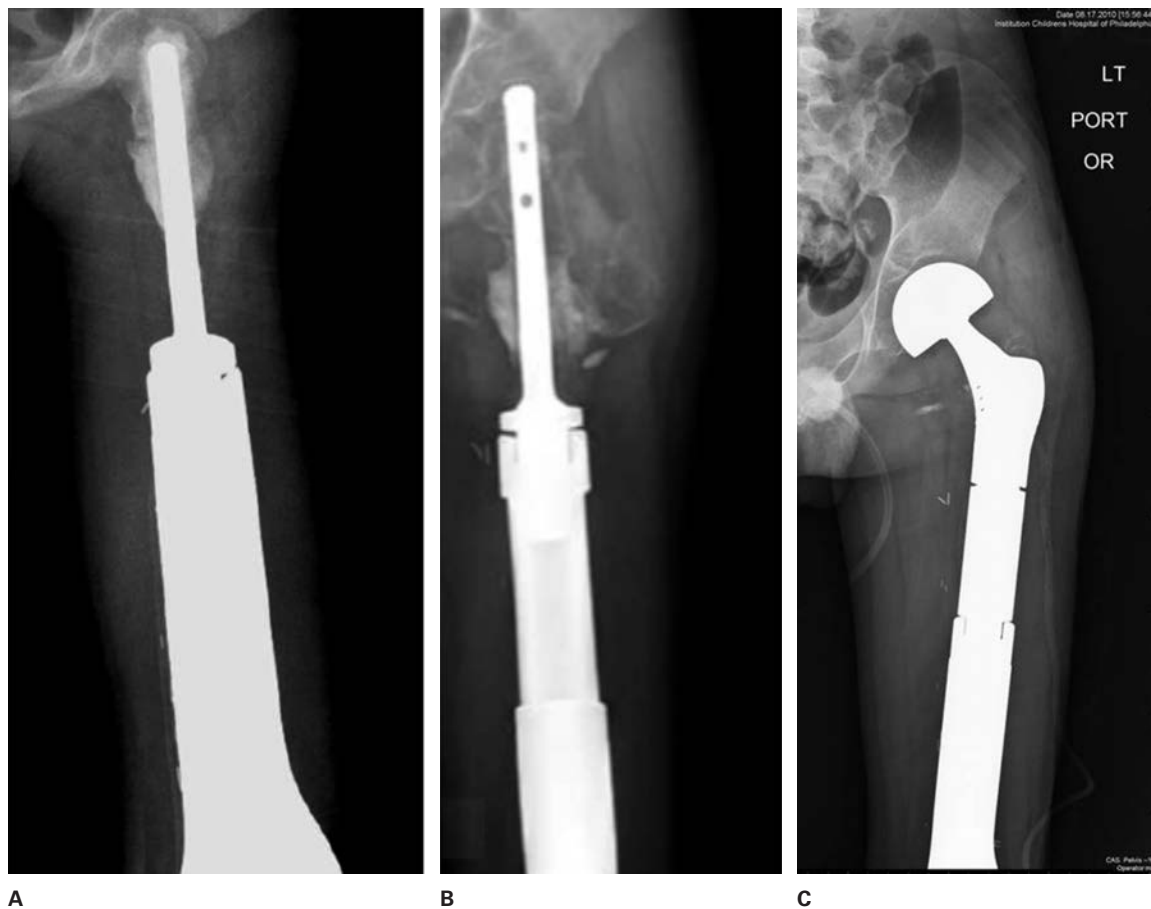
A six-year-old boy was referred to our clinic with a history of left distal thigh pain for two and half weeks, associated with a very painful and large antero-lateral mass. Biopsy confirmed the diagnosis of osteosarcoma. Staging studies revealed no metastasis (stage IIB). The MRI performed after neo-adjuvant chemotherapy treatment showed an extensive involvement of the femoral diaphysis (Fig.1). Wide resection



**Figure 1:** Preoperative sagittal T1 weighted view- fat suppression MRI showing extensive intramedullary involvement of the left femoral diaphysis in a 6-year-old patient with osteosarcoma.

### Corresponding author:

Juan Pretell-Mazzini, MD  
Pediatric Orthopaedic Surgeon  
Pediatric Unit  
“12 de Octubre” Hospital  
Department of Orthopaedic Surgery  
Madrid, Spain, 28041  
el\_giova23@yahoo.com

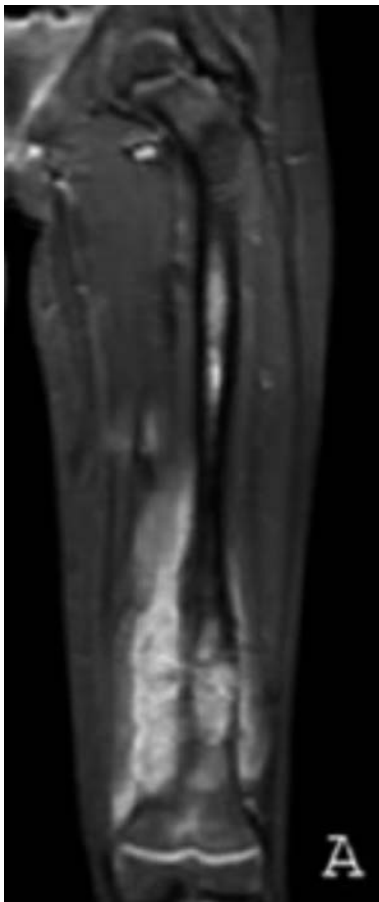

**Figure 2:** Post-operative follow up in a 6-year-old patient with osteosarcoma of the left femur. (A) AP plain x-ray view showing femoral endoprosthetic reconstruction after intertrochanteric osteotomy and verticalization of the proximal femur. (B) AP plain radiograph showing endoprosthetic femoral reconstruction and proximal migration of the femoral stem with subsequent destruction of femoral head. A hemiarthroplasty was planned. (C) AP plain radiograph of the pelvis immediately following revision surgery.

of the left femur with its surrounding soft tissue mass was performed. The C-arm was utilized and a femoral osteotomy was performed through the intertrochanteric region approximately one centimeter proximal to signal abnormality on MRI with an attempt to preserve the greater trochanter abductor insertion as well as hip joint. Reconstruction was performed using a custom made Stryker-Howmedica expandable endoprosthesis (percutaneous lengthening mechanism) with a custom made femoral stem (Fig.2A). Margins were free of sarcoma. The patient's immediate post-operative course was uneventful; he soon began our rehabilitation protocol. A follow-up CT of the chest revealed no metastasis. He underwent a total of five expansions during a six year period of time before proximal migration of the femoral stem with subsequent perforation of the femoral head occurred (Fig.2B). A hemiarthroplasty with a proximal femoral bipolar endoprosthesis was performed at this time (Fig.2C). Since then, the patient has undergone two additional expansions. At 80 months follow up, he is clinically well, continuously disease free with no limb length discrepancy, walks with a slight Trendelenburg gait and has a normal acetabular shape with no subluxation and a clinically stable hip joint.

### Case 2

A nine-year-old girl with a history of retinoblastoma status post chemotherapy and eye enucleation was referred to our clinic with a two week history of left distal thigh pain after trauma, associated with tenderness in that area. Initial plain x-rays showed a mixed lytic and sclerotic bone lesion in the distal femur associated with periosteal reaction. The diagnosis of osteosarcoma was confirmed by biopsy with a IIB stage. The MRI performed after neo-adjuvant chemotherapy treatment revealed an extensive femoral diaphyseal involvement with a proximal skip lesion (Fig.3A). A wide resection of the left femur with its surrounding soft tissue mass was performed. The C-arm was utilized and a femoral osteotomy was performed through the intertrochanteric region with an attempt to preserve the greater trochanter abductor insertion as well as hip joint. Reconstruction was performed using a custom made Stryker-Howmedica expandable endoprosthesis (percutaneous lengthening mechanism) with a custom made femoral stem and verticalization of the proximal femur. Margins were free of sarcoma. The patient's immediate post-operative course was uneventful; she soon started our rehabilitation protocol. A follow-up CT of the chest revealed no metastasis. She underwent a total of three expansions during a 4.5 year



**Figure 3:** Pre-operative coronal T1 weighted view – fat suppression MRI showing skip intramedullary involvement of the left femoral diaphysis of a nine year old girl with left femoral osteosarcoma undergoing reconstruction with a second generation expandable endoprosthesis.

period of time. At 55 months of follow up, she has a LLD of 2.8 cm (Fig 4A) and underwent a contralateral epiphysiodesis (distal femur, proximal tibia and proximal fibula). She is doing clinically well, with limping due to the LLD, is continuously disease free, with preservation of the native hip and has a well shaped acetabulum (Fig.4B) with no clinical hip instability.

## Discussion

Acetabular development following femoral hemiarthroplasty in the skeletally immature patient has not been well described. Young adults with a bipolar hip hemiarthroplasty have developed progressive proximal migration and medial translation<sup>12</sup>, whereas patients with juvenile rheumatoid arthritis develop progressive protrusio acetabuli<sup>13</sup>.

It has been described that following hemiarthroplasty of the hip in the skeletally immature, the acetabulum has a tendency to become shallower, with a decreasing centre-edge angle and an increase in lateral translation. In addition, the hip center rises with proximal migration of the prosthesis. This is more apparent in patients younger than 11 years of age<sup>11</sup>.

In most studies in which the proximal segment of the femur is replaced, dislocation is one of the most common complications reported. Kenan and Lewis reported difficulty

in maintaining containment of the femoral head in all children who had an expandable proximal femoral prosthesis<sup>14</sup>; Manoso et al also reported hip instability in all the patients included in his study<sup>11</sup> and Belthur et al<sup>14</sup> found hip instability in 44% of cases. This instability could be related to the acetabular configuration and the relative lack of abductor strength<sup>10,15</sup>.

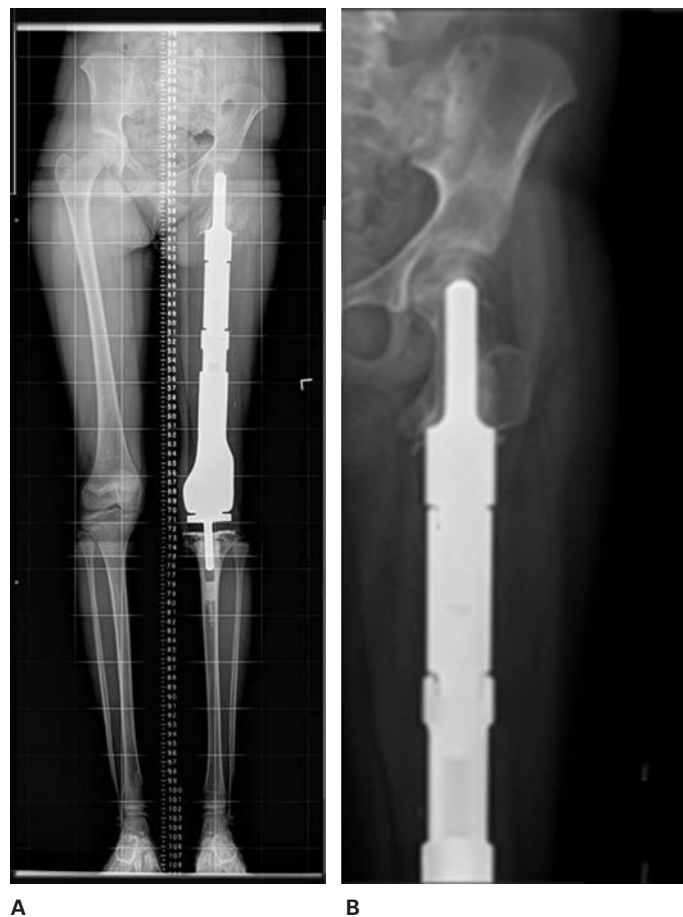The normal acetabulum deepens and enlarges with maturity<sup>11</sup>. During normal development, cupping of the acetabulum occurs by the age of three, with greater ossification of the posterior wall than the anterior wall. By the age of five, the child's acetabulum has clearly undergone progressive deepening, and by the age of 11, the triradiate cartilage has begun to close. Once a child reaches the age of 13, the triradiate cartilage has closed and the acetabulum has assumed a spherical configuration<sup>16</sup>. This normal development could be interrupted when a hemiarthroplasty is used due to an increase in pressure and greater wear on the cartilage surface and subchondral bone of the acetabular dome from the smaller head component. When a total femoral reconstruction is performed using an endoprosthesis, the proximal segment may affect the acetabulum as mentioned above, associated with a relative weakness of the abductor apparatus depending on the quality of its reconstruction.

In the two cases presented in this report, a near total femoral involvement was observed in both patients; according to some authors<sup>5,7</sup> this would be an indication for a total femoral reconstruction. Based on the possible acetabula development arrest and the abductor apparatus issues, we decided to preserve the native hip joint without sacrificing free margins. The post-chemotherapy MRI is of utmost importance in achieving this goal; this is a useful guidance in order to know the level of the osteotomy. In our two cases we were able to perform an intertrochanteric osteotomy based on this fact.

Our two patients were very young at the time of first surgery and their acetabula were at a critical stage of development. Performing an osteotomy at this level preserves the native femoral head with the subsequent apposition to the acetabulum allowing for a normal development. Even though the first case presented with a proximal femoral stem migration and a conversion to a hemiarthroplasty was needed, there was no abnormal development of the acetabula because there was enough time for the triradiate cartilage to close with subsequent normal acetabula development.

Another factor that affects hip stability is the relative lack of abductor strength due to resection of the soft tissue mass with the subsequent decrease in the functional muscle mass left as well as the quality of reattachment of the muscles into the prosthesis. Some authors suggest that implantation of the prosthesis with increased offset or a more varus prosthesis may help to maintain the femoral head in the acetabulum<sup>11</sup>. Performing an intertrochanteric osteotomy such as we did, may allow preservation of the native insertions of the abductor muscles and the verticalization of the proximal femur gives more tension to those muscles with subsequent joint stability.

The very low number of patients reported in this study does not allow us to make strong conclusions or recommendations. However, we think that our approach



**Figure 4:** Post-operative follow up in a 9-year-old patient with osteosarcoma of the left femur. (A) AP 32-inch plain radiograph showing 2.8 cm of LLD. (B) AP plain radiograph of the pelvis showing normal development of the acetabula and a congruent hip joint.

to this clinical scenario could be an alternative to a total femoral replacement in the appropriate patient. MRI images play an important role in defining the limits of the femoral involvement and the suitability for an osteotomy to be performed. We never have to sacrifice free margins of resection and do the osteotomy if this could be achieved. We think that preserving the proximal femoral segment will maintain hip stability through a normal acetabula development and congruency between the femoral head and acetabulum as well as preserving an acceptable function of the abductors muscle.

## References

1. Eckardt JJ, Safran MR, Eilber FR. Expandable endoprosthetic reconstruction of the skeletally immature after malignant bone tumor resection. *Clin Orthop*. 1993;188-202.
2. Gupta A, Meswania J, Pollock R. Non-invasive distal femoral expandable endoprosthesis for limb-salvage surgery in paediatric tumours. *J Bone Joint Surg[Br]*. 2006;88:649-654.
3. Henderson ER, Pepper AM, Marulanda GA. What is the emotional acceptance after limb salvage with an expandable prosthesis? *Clin Orthop*. 2010;468:2933-38.
4. Wilkins RM, Soubeiran A. The phenix expandable prosthesis: Early american experience. *Clin Orthop*. 2001;51-58.
5. Natarajan MV, Balasubramanian N, Jayasankar V. Endoprosthetic reconstruction using total femoral custom mega prosthesis in malignant bone tumours. *Int Orthop*. 2009;33:1359-1363.
6. Ahmed AR. Total femur replacement. *Arch Orthop Trauma Surg*. 2010;130:171-176.
7. Jeon DG, Kim MS, Cho WH. Clinical outcome of osteosarcoma with primary total femoral resection. *Clin Orthop*. 2007;457:176-182.
8. Gerrand CH, Currie D, Grigoris P. Prosthetic reconstruction of the femur for primary bone sarcoma. *Int Orthop*. 1999;23:286-290.
9. Schindler OS, Cannon SR, Briggs TW. Use of extendable total femoral replacements in children with malignant bone tumors. *Clin Orthop*. 1998:157-170.
10. van Kampen M, Grimer RJ, Carter SR. Replacement of the hip in children with a tumor in the proximal part of the femur. *J Bone Joint Surg[Am]*. 2008;90:785-795.
11. Manoso MW, Boland PJ, Healey JH. Acetabular development after bipolar hemiarthroplasty for osteosarcoma in children. *J Bone Joint Surg[Br]*. 2005;87:1658-1662.
12. Donati D, Zavatta M, Gozzi E. Modular prosthetic replacement of the proximal femur after resection of a bone tumour a long-term follow-up. *J Bone Joint Surg[Br]*. 2001;83:1156-1160.
13. Yun AG, Martin S, Zurakowski D. Bipolar hemiarthroplasty in juvenile rheumatoid arthritis: Long-term survivorship and outcomes. *J Arthroplasty*. 2002;17:978-986.
14. Belthur MV, Grimer RJ, Suneja R. Extensible endoprostheses for bone tumors of the proximal femur in children. *J Pediatr Orthop*. 2003;23:230-235.
15. Kabukcuoglu Y, Grimer RJ, Tillman RM. Endoprosthetic replacement for primary malignant tumors of the proximal femur. *Clin Orthop*. 1999:8-14.
16. Weiner LS, Kelley MA, Ulin RI. Development of the acetabulum and hip: Computed tomography analysis of the axial plane. *J Pediatr Orthop*. 1993;13:421-425.