



The Use of Press-fit Stems in Revision Total Knee Arthroplasty

¹P. Maxwell Courtney, MD

¹Neil P. Sheth, MD

²Wayne G. Paprosky, MD

¹Department of Orthopaedic Surgery,
University of Pennsylvania,
Philadelphia, PA

²Department of Orthopaedic Surgery,
Rush University Medical Center,
Midwest Orthopaedics, Chicago, IL

Introduction

The routine use of stems has been shown to improve the outcomes and survival rate in revision total knee arthroplasty.¹⁻³ Stems are widely used to supplement component fixation, acting to bypass bone defects, offload deficient bone, and reduce interface stresses of damaged bone in the distal femur and proximal tibia. The optimal method of stem fixation in revision TKA, however, continues to be debated in the literature. Several studies have demonstrated good long-term clinical results with cemented stems in revision TKA.^{4,6} Cemented stems provide immediate fixation with less intrusion into the intramedullary canal, however they can present a challenge to remove and theoretically increase stress shielding surrounding the metaphyseal bone.

More recently, some orthopaedic surgeons have advocated the use of a press-fit diaphyseal stem with cement in the metaphyseal portion of the implant. The use of a long stem that fills the intramedullary canal and engages diaphyseal bone has been shown to improve component alignment.⁷ In biomechanical studies, short, cemented stems have shown equivalent strength of fixation with longer press-fit stems.⁸ In this review, we will describe the indications, surgical technique, and clinical results of this hybrid technique for fixation in revision TKA.

Indications

Press-fit stems should be considered for all patients with a failed primary total knee arthroplasty. Patients must have structural integrity of both the femoral and tibial canals to accommodate a wider press-fit stem. The intramedullary canals should be correlated with the mechanical axis of the limb as the stem will dictate the position of the components. Care should be taken to make sure the components are appropriately lateralized for patellar tracking, as longer press-fit stems can result in improper component positioning, particularly the tibia where the canal is posteromedial relative to the plateau. Most manufacturers make offset stems to solve this problem. Those patients with large metaphyseal bone defects and soft tissue laxity

are also good candidates for press-fit stems. Longer uncemented stems will bypass the bony defect and provide more support in both the rotational and bending planes.

There are several relative contraindications to the use of uncemented stems in revision TKA. Patients with wide, osteopenic intramedullary canals often require cement fixation. In the setting of infection, press-fit stems are unable to deliver local antibiotics as in the case of a fully cemented canal. End-of-stem pain has also been described with older cobalt chromium uncemented stems, however newer fluted titanium stems have experienced this problem less frequently.

Surgical Technique

Here we explain the surgical technique used by the authors for hybrid fixation in revision TKA. Regardless of the type of fixation that is chosen, adequate surgical exposure must be obtained in order to gain proper visualization and allow for safe removal of implants with minimal iatrogenic bone loss. Following implant removal, a thorough debridement of all fibrous tissue and remaining cement must be performed to allow for proper implant fixation to host bone and to avoid eccentric canal reaming and potential perforation due to retained cement. Femoral and tibial intramedullary canal debridement can be facilitated with using instruments such as the “back scraper” and cement removing osteotomes typically found in the Depuy Moreland set (Warsaw, IN). Attention should first be turned to reconstruction of the tibia, as tibial reconstruction can affect both the flexion and extension space and acts as a foundation for revision TKA.

Tibial component revision begins with a “freshen up” cut on the tibia. This resection can be performed using a “free-hand” technique, with the use of an extramedullary guide, or with an intramedullary guide and an attached resection guide. The author's preference is to make tibial resection with an intramedullary guide with a 0 degree slope resection guide. The tibial canal is either reamed by hand or on power to determine the appropriate sizing of type of

Corresponding author:

P. Maxwell Courtney, MD
Penn Medicine University City
3737 Market Street, 6th Floor
Philadelphia, PA 19107
Phone: 215-662-3340
paul.courtney@uphs.upenn.edu

canal. Once the canal diameter has been determined, a reamer handle is left in the canal and used as a guide for the resection. A common tendency is to undersize the femoral and tibial stems in order to avoid creating a periprosthetic fracture.

Typically, a tibial resection guide is secured in position over the intramedullary guide with two drill pins as the remaining anterior cortical tibial bone is often sclerotic making placement of mechanical pins with a mallet difficult and inaccurate. The 0 degree guide allows for the resection to be made from any position—medial or central, depending on the ability of the patellar tendon to be mobilized laterally. Guides that are sloped can result in a varus resection if the cut is made medial to lateral, resulting in a biplanar proximal tibial resection.

Following the tibial resection, the intra-medullary reamer is maintained in position and a tibial sizing tray of the appropriate size is placed in the proper external rotation. An offset bushing is often available from most manufacturing companies to determine the necessary amount of offset needed for reconstruction. Most revision TKA systems offer anywhere from 4-8 mm of offset. Most commonly, the tibial tray

sits posterior and lateral from the intra medullary tibial canal. Drill pins are used to secure the tray in its final position and the degree of offset is recorded. A drill and a punch are used for final preparation of the proximal tibia. All instrumentation is removed and the trial tibia with the appropriate diameter offset stem in the proper offset position is assembled and placed on the tibia. A 100 mm length stem is typically used for the tibial reconstruction (Figure 1).

Attention is now turned to the femur for reconstruction. In the setting of revision TKA, it is typical to be looser in flexion than in extension and often times, the tendency is to raise the joint line. Most commonly, the femoral component that was removed is upsized one size and an augment is placed posterolaterally (to assist with component external rotation) with an augment placed both distal medial and distal lateral (to avoid creating excessive patella baja). The femoral canal

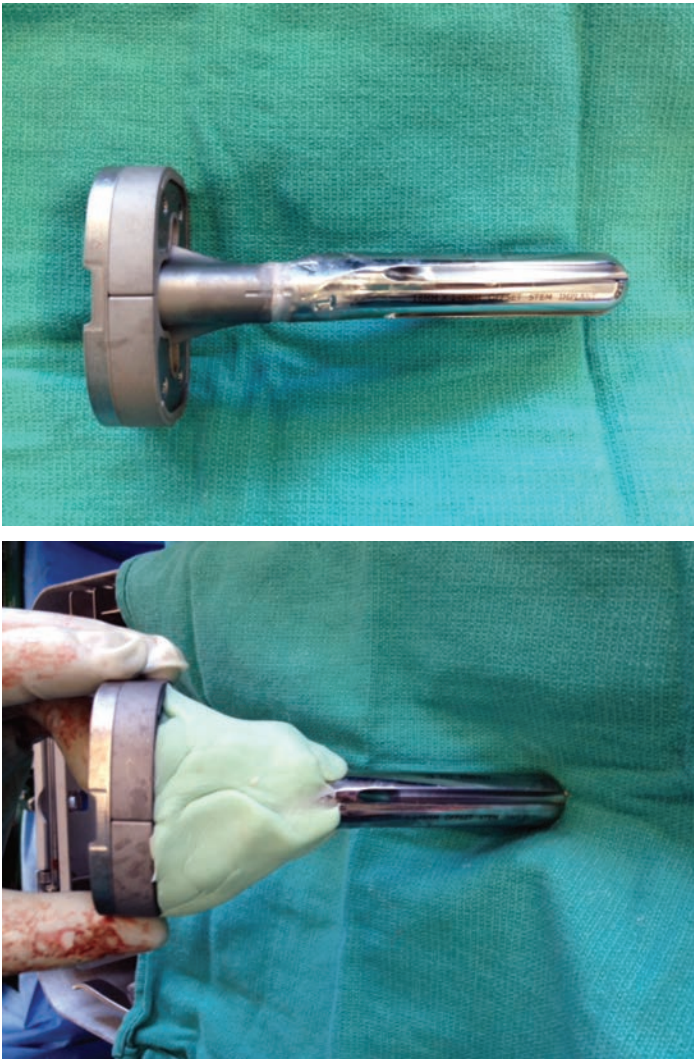


Figure 1. Hybrid fixation of the tibial component. Bone wax is applied to the interface between the metaphyseal component and the stem to facilitate removal if further revision is necessary (A). Cement is applied to the metaphyseal component of the implant.

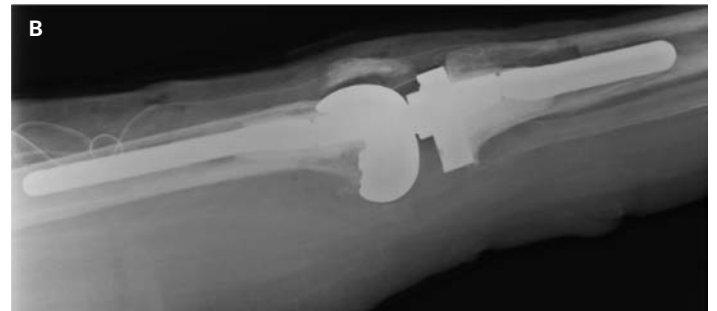
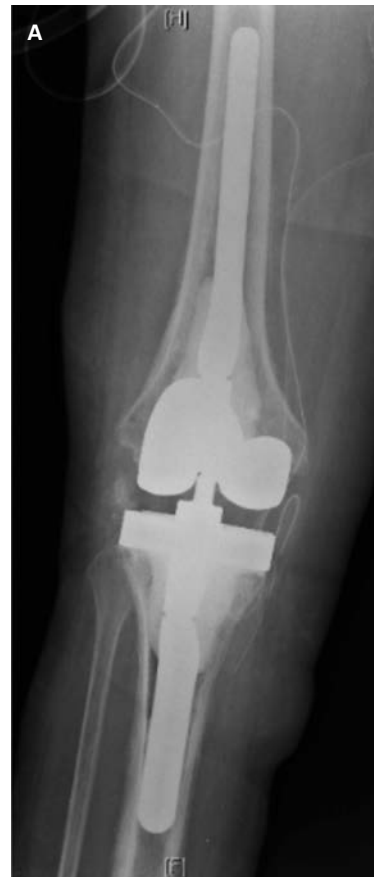
Figure 2. AP (A) and lateral (B) postoperative radiographs of a patient undergoing revision TKA with press fit femoral and tibial stems and cemented metaphyseal components.

Table 1. Summary of clinical results of studies for the use of press-fit stems in revision total knee arthroplasty.

Study	# Patients	Knee Society score (preop-postop)	Aseptic revision rate	Survivorship
Hass et al (1995) ¹¹	76	49-76	2.6% at 3 yrs	83% at 8 yrs
Gofton et al (2002) ¹²	89	40-52	4.5% at 5.9 yrs	93.5% at 8.6 yrs
Shannon et al (2003) ¹³	63	56-81	10% at 5.7 years	84% at 6 years
Fehring et al (2003) ⁴	95			71% "stable"
Bottner et al (2006) ¹⁴	33	42-83	6% at 3 yrs	
Wood et al (2009) ¹⁰	135	55-86	1.5% at 5 yrs	87% at 12 yrs
Sah et al (2011) ⁹	88	46-85	90% at 40 months	92% at 5 yrs, 84% at 10 yrs
Manopoulos et al (2012) ¹⁵	46	42-84 (IKS score)	4.3% at 8.5 yrs	90% at 10 yrs
Iamaguchi et al (2013) ¹⁶	34	35-81		100% at 2.2 yrs

is again reamed either by hand or on power to determine the appropriate canal diameter. Once the diameter has been chosen, one diameter smaller is often selected for the purpose of trialing. The offset stem is typically placed in a posterior position; however, the stem is placed on the trial femur in a loose manner so the canal and the remaining host femoral condyles can assist in finding the correct alignment and component position, respectively. The stem length on the femoral side is typically longer and is in judge range of 150mm.

Once the final component sizes have been chosen for both the femur and the tibia, all trial components are removed and the final components are assembled on the back table. Typically two batches of cement, with a total of 2 grams of antibiotics per batch of cement, are used for cementation of each component. The tibial component is cemented in position first—the cement is placed under the tibial tray to include the modular junction and slightly beyond. The same cement technique is used for the femur. All excess cement is removed and a trial polyethylene of the appropriate thickness is placed in position while the knee is brought out to full extension during the cement curing process.

The stems in this type of reconstruction are used to assist with construct alignment as well as protection of the remaining host metaphysical bone stock. The stems are NOT in-growth surfaces, however act as a “deep nice-post” to perform the functions previously stated (Figure 2). This technique demonstrates why undistinguished placement of the stem on both the femoral and tibial sides is suboptimal, as an undersized stem may not result in appropriate stability of the construct and lead to early loosening.

Clinical Results

Clinical results have demonstrated favorable mid-term clinical outcomes for press-fit stems in revision TKA. Table 1 summarizes the clinical studies. In a retrospective series of consecutive patients undergoing revision TKA with a hybrid technique, Sah et al reported 92% survivorship at 5 years and 84% survivorship at 10 years.⁹ Wood et al reported similar results with a survivorship from aseptic loosening of 98% at

12 years.¹⁰ Patients in both series reported good functional outcomes. Although prospective studies comparing cemented stems and hybrid fixation with long follow-up are still needed, press-fit stems are a reliable option for fixation in revision total knee arthroplasty.

References

1. Bertin KC, Freeman MA, Samuelson KM, et al. Stemmed revision arthroplasty for aseptic loosening of total knee replacement. *J Bone Joint Surg Br*, 67(2):242–248 (1985).
2. Bourne RB, Finlay JB. The influence of tibial component intramedullary stems and implant-cortex contact on the strain distribution of the proximal tibia following total knee arthroplasty: An in vitro study. *Clin Orthop Relat Res*, 208 (1986)
3. Brooks PJ, Walker PS, Scott RD. Tibial component fixation in deficient tibial bone stock. *Clin Orthop Relat Res*, 184:302–308 (1984).
4. Fehring TK, Odum S, Olekson C, et al. Stem fixation in revision total knee arthroplasty: a comparative analysis. *Clin Orthop Relat Res*, 416:217-224 (2003).
5. Murray PB, Rand JA, Hanssen AD. Cemented long-stem revision total knee arthroplasty. *Clin Orthop Relat Res*, 309:116-112 (1994).
6. Maybry TM, Vessely MB, Schleck CD, et al. Revision total knee arthroplasty with modular cemented stems: long-term follow-up. *J Arthroplasty*, 22(suppl):100-5 (2007).
7. Parsley BS, Sugano N, Bertolusso R, et al. Mechanical alignment of tibial stems in revision total knee arthroplasty. *J Arthroplasty*, 18:33-36 (2003).
8. Peters CL, Craig MA, Mohr RA, et al. Tibial component fixation with cement: full versus surface-cementation techniques. *Clin Orthop Relat Res*, 409:156-168 (2003).
9. Sah AP, Shukla S, Della Valle CJ, et al. Modified hybrid stem fixation in revision TKA is durable at 2 to 10 years. *Clin Orthop Relat Res*, 469(3):839-46 (2011).
10. Wood GC, Naudie DD, MacDonald SJ, et al. Results of press-fit stems in revision knee arthroplasties. *Clin Orthop Relat Res*, 467(3):810-7 (2009).
11. Haas SB, Insall JN, Montgomery W 3rd, et al. Revision total knee arthroplasty with use of modular components with stems inserted without cement. *J Bone Joint Surg Am*, 77:1700–1707 (1995).
12. Gofton WT, Tsigaras H, Butler RA, et al. Revision total knee arthroplasty: fixation with modular stems. *Clin Orthop Relat Res*, 404:158–168 (2002).
13. Shannon BD, Klassen JF, Rand JA, et al. Revision total knee arthroplasty with cemented components and uncemented intramedullary stems. *J Arthroplasty*, 18(suppl 1):27–32 (2003).
14. Bottner F, Laskin R, Windsor RE, et al. Hybrid component fixation in revision total knee arthroplasty. *Clin Orthop Relat Res*, 446:127–131 (2006).
15. Manopoulos P, Havet E, Pearce O, et al. Mid- to long-term results of revision total knee replacement using press-fit intramedullary stems with cemented femoral and tibial components. *J Bone Joint Surg Br*, 94(7):937-40 (2012).
16. Iamaguchi MM, de Castro FB, Gobbi RG, et al. Results of revision total knee arthroplasty using press-fit cementless stem. *Acta Orthop Bras*, 21(1):23-6 (2013).