



Triceps Tendon Reconstruction in the Setting of Elbow Stiffness: A Surgical Technique

Mohit Gilotra, MD

G. Russell Huffman, MD, MPH

Introduction

Elbow stiffness may significantly interfere with activities of daily living.¹ Loss of elbow flexion is particularly debilitating with respect to eating, personal hygiene, phone use and occupational specific tasks.^{2,3} An elbow contracture can result from trauma, burns, central neurologic spasticity and even prolonged immobilization. The etiology may broadly be classified as extra-articular or intra-articular and the treatment is adjusted accordingly.⁴ Specific intra-articular diagnoses include: joint incongruity; arthritis; loose bodies; capsular contracture; and osteophyte impingement. Extra-articular etiologies consist of: heterotopic ossification; contractures of skin, collateral ligament, peri-articular muscles and tendons.⁵

Evaluation starts with a complete history and examination. Physical examination includes an assessment of range of motion and a neurovascular exam. The ulnar nerve location, sensory and motor function, and sensitivity to palpation are especially important in the evaluation.

Radiographic evaluation begins with orthogonal anteroposterior, lateral and oblique views. Computed tomography with three-dimensional reconstructions and, when appropriate, metal subtraction further characterizes bone that is essential to remove during surgery for full restoration of motion.

Non-operative treatment is the initial treatment for an elbow contracture in which a clear mechanical obstruction to motion is absent. In these patients, effective treatments include edema control, minimizing inflammation and the use of static progressive stretching and splinting. However, once an elbow contracture is established and is refractory to these measures, surgical contracture release, either arthroscopic or open, has been shown to be safe and effective. Traditionally, indications for surgery include inability of the patient to regain a functional flexion extension arc, which is most commonly defined as a 100-degree arc of motion (i.e., at least a 30° elbow contracture or inability to flex beyond 130°).¹ Certain patients may require further range of motion based on occupational or sporting activities.³

In this report, we describe the treatment of an extra-articular elbow contracture in which the patient lacked elbow flexion beyond 40 degrees. Restoration of elbow flexion was achieved through surgical lengthening of the triceps tendon using a tendon reconstruction technique after a complete capsulectomy. This step-wise approach is indicated for patients who have an extra-articular explanation for stiffness and a congruent non-arthritic joint.⁶

Case

A 38 year-old male presented with a chief complaint of elbow stiffness and an inability to bend his arm. He originally sustained an open midshaft humerus fracture from a crush injury four years ago treated with an elbow-spanning external fixator. He then developed a chronic nonunion treated with a free vascular fibular graft and revision internal fixation 18 months prior to presentation. He had no complaints of elbow pain and no ulnar nerve symptoms. On examination, he had a 20° elbow extension contracture and lacked flexion beyond 40°. Radiographs of the humerus demonstrated a healed fracture with stable hardware (Fig 1a, 1b). Elbow imaging showed a congruent joint and no signs of arthritis. His lack of motion was attributed to both intra- and extra-articular contractures.

He underwent an open contracture release in the lateral decubitus position utilizing a posterior approach. The ulnar nerve was transposed in an anterior subcutaneous position and the posterior bundle of the medial collateral ligament was released. Complete anterior and posterior capsular excisions were performed and his motion was reassessed with an achieved flexion-extension arc from 5 to 90°. Elevation of the triceps tendon from the humeral shaft did not improve elbow flexion. The triceps insertion was then sequentially released from the medial aspect of the olecranon until elbow flexion reached 130 degrees. Approximately 75% of the tendon had been released at the triceps enthesis. The triceps insertion was then reconstructed using a previously published technique¹³ utilizing a non-irradiated semitendinosus allograft.

Corresponding author:

G. Russell Huffman MD, MPH
Penn Medicine University City
3737 Market Street, 6th Floor
Philadelphia, PA 19107
Phone: 215-662-3340
GeorgeRussell.Huffman@uphs.upenn.edu

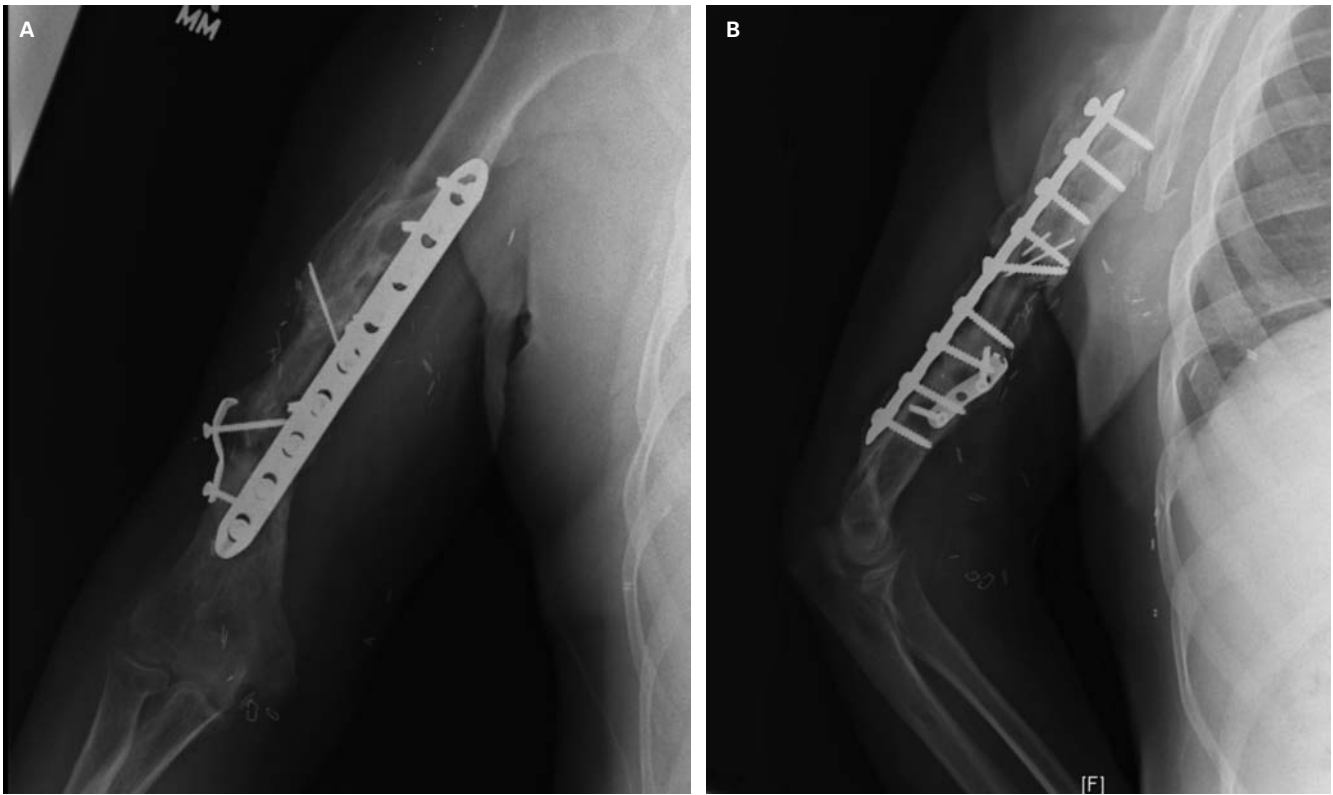


Figure 1. (A & B) AP and lateral radiographs of the distal humerus show healed nonunion. There is no radiographic evidence of an intra-articular elbow pathology.

Operative Technique

Preoperatively, the patient is asked about ulnar nerve symptoms and examined for subluxation, pain and weakness. An ulnar nerve transposition is planned if there is a positive exam or if the patient lacks 90 degrees of flexion.

Prior to surgery, the patient receives either a supraclavicular or interscalene nerve block. A nerve block or an indwelling catheter helps reduce intraoperative narcotic requirements, postoperative nausea and aids in maintaining passive range of motion in the immediate postoperative period.⁷

While the patient is under anesthesia, a full elbow exam is performed assessing range of motion and stability. The patient may be positioned supine with the arm extended on a hand table or lateral decubitus with the arm placed over a padded Mayo stand. A tourniquet is placed proximally and the arm is prepped and draped sterilely.

Prior incisions around the elbow are assessed and a straight posterior incision is preferred. Limited medial and/or lateral approaches are options as well.^{8,9} A full thickness dissection is performed to the triceps tendon. The ulnar nerve is identified, protected and prepared for a transposition as indicated. It is released proximally to the Arcade of Struthers and distally to the first FCU branch. The intermuscular septum is excised and both the articular and motor branches to the FCU are sacrificed if needed to minimize nerve tension.

After the ulnar nerve is protected, the floor of the cubital tunnel or the posterior bundle of the MCL is released, particularly in patients lacking adequate elbow flexion.

Laterally, dissection is carried down to the lateral column of the humerus. The triceps is elevated posteriorly exposing the olecranon fossa where posterior capsule and scar are excised. Any osteophytes on the olecranon or the humerus blocking extension are removed.

Exposure anteriorly may be obtained medially or laterally. The author's preferred technique is through a medial or Hotchkiss approach. The flexor pronator origin is longitudinally incised and the anterior two-thirds is reflected from the medial epicondyle with preservation of the anterior bundle of the medial collateral ligament. The brachialis and the anterior portion of the flexor pronator mass are elevated to visualize the anterior capsule. After the capsule is excised, the coronoid and radiocapitellar joint are debrided.

If flexion is still not obtained with the above maneuvers, then a triceps release is planned. While the elbow is placed in maximal flexion, the triceps is partially elevated from the olecranon medially with elevation continuing laterally as needed. When possible, the fascia contiguous between the triceps and anconeus is left intact to protect the remaining triceps tendon and remnant native extensor mechanism. Elbow flexion is re-examined after these steps to ensure satisfactory gains.

A triceps tendon reconstruction is then performed to augment the insertion site. A running locking stitch using non-absorbable braided suture is passed along both ends of either auto- or allograft tendon. Transosseous tunnels are drilled in a crossing fashion through the olecranon process

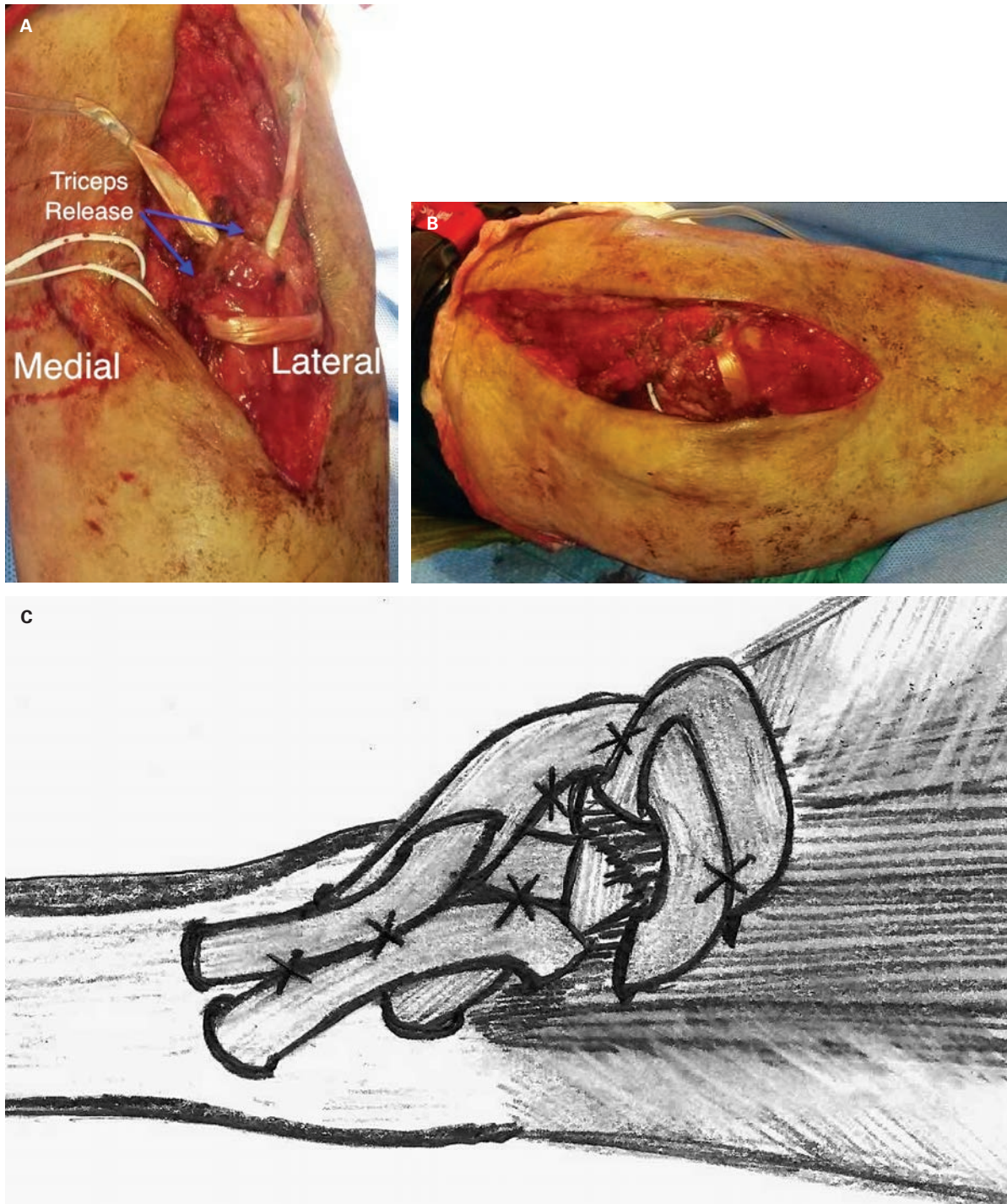


Figure 2. (A) A semitendinosus allograft passed through bone tunnels. (B) A pulvertaft weave is woven through the triceps tendon. (C) A sketch diagram of the triceps reconstruction technique.

using a 4.0 mm cannulated reamer over guidewires with care taken to preserve the dorsal cortical integrity of the bone. The graft is passed through the bone tunnels and then through the triceps tendon using a Pulvertaft weave (Fig 2a-c). The graft is tensioned and sutured back to itself in 90 degrees of flexion. The graft is additionally sutured to the tendon in multiple places using non-absorbable suture on a tapered needle. The

reconstruction tensioning is then assessed through full range of motion.

The tourniquet is then deflated and hemostasis achieved. The ulnar nerve is transposed into a subcutaneous position usually within an adipose sling. A submuscular transposition is an option as well. The wound is irrigated and a drain is placed prior to closure. When possible, the incision should

be placed medial or lateral to midline to avoid postoperative wound complications, particularly when the surgical goal is restoration of elbow flexion.

A splint is placed in 90 degrees of flexion and neutral forearm rotation for two days. Self directed range of motion is started with active-assisted flexion and gravity-assisted extension. Active elbow extension is recommended at four to six weeks.

Discussion

Contracture release for elbow stiffness is effective regardless of an open or arthroscopic approach.^{10,11} A medial, lateral or posterior approach results in the same range of motion gains as long as all sites of pathology are addressed.⁹ Combined intra- and extra-articular contractures are particularly challenging and a myotendinous contracture of the triceps is one of the more difficult sites to treat. Options include a triceps slide and V-Y lengthening to gain flexion. All of these techniques can lead to extensor mechanism failure or lack of strength with active elbow extension. Most of the literature has focused on children with arthrogyposis, where a posterior capsulotomy in addition to triceps lengthening had significant gains of passive flexion.¹²

The technique of triceps reconstruction used in this case has been described for chronic triceps rupture.¹³ Hamstring autograft was used in two recent case reports.^{14,15} Other described tissue transfers include Achilles, plantaris, and latissimus. Anconeus and palmaris may be used from the same extremity.¹⁶ In another report, V-Y advancement with plantaris autograft was used to augment a repair.¹⁷

In the setting of extra-articular elbow stiffness, a triceps contracture commonly reduces elbow flexion. The authors advocate consideration of a partial triceps release with allograft reconstruction. This technique provides gains in flexion while optimizing reconstruction strength and allowing early postoperative motion.

References

- Morrey BF, Askew LJ, Chao EY.** A biomechanical study of normal functional elbow motion. *J Bone Joint Surg Am* (1981).
- Vasen AP, Lacey SH, Keith MW, et al.** Functional range of motion of the elbow. *J Hand Surg* (1995).
- Sardelli M, Tashjian RZ, MacWilliams BA.** Functional elbow range of motion for contemporary tasks. *J Bone Joint Surg Am* (2011).
- Morrey BF.** Post-traumatic contracture of the elbow. Operative treatment, including distraction arthroplasty. *J Bone Joint Surg Am* (1990).
- Charalambous CP, Morrey BF.** Posttraumatic elbow stiffness. *J Bone Joint Surg Am* (2012)
- Lindenhovius AL, Doornberg JN, Ring D, et al.** Health status after open elbow contracture release. *J Bone Joint Surg Am* (2010).
- Cohen NP, Levine WN, Marra G, et al.** Indwelling interscalene catheter anesthesia in the surgical management of stiff shoulder: a report of 100 consecutive cases. *J Shoulder Elbow Surg* (2000).
- Mansat P, Morrey BF.** The column procedure: a limited lateral approach for extrinsic contracture of the elbow. *J Bone Joint Surg Am* (1998).
- Tan V, Daluiski A, Simic P, et al.** Outcome of open release for post-traumatic elbow stiffness. *J Trauma* (2006).
- Nguyen D, Proper SI, MacDermid JC, et al.** Functional outcomes of arthroscopic capsular release of the elbow. *Arthroscopy* (2006).
- Ball CM, Meunier M, Galatz LM, et al.** Arthroscopic treatment of post-traumatic elbow contracture. *J Shoulder Elbow Surg*, (2002).
- Van Heest A, James MA, Lewica A, et al.** Posterior elbow capsulotomy with triceps lengthening for treatment of elbow extension contracture in children with arthrogyposis. *J Bone Joint Surg Am* (2008).
- Scolaro JA, Blake MH, Huffman GR.** Triceps tendon reconstruction using ipsilateral palmaris longus autograft in unrecognized chronic tears. *Orthopedics* (2013).
- Weistroffer CDR, Mills WJ, Shin AY.** Recurrent rupture of the triceps tendon repaired with hamstring tendon autograft augmentation: a case report and repair technique. *J Shoulder Elbow Surg* (2003).
- Dos Remedios C, Brosset T, Chantelot C, et al.** Repair of a triceps tendon rupture using autogenous semi-tendinous and gracilis tendons. A case report and retrospective chart review. *Chir Main* (2007).
- Van Riet RP, Morrey BF, Ho E, et al.** Surgical treatment of distal triceps ruptures. *J Bone Joint Surg Am* (2003).
- Wagner JR, Cooney WP.** Rupture of the triceps muscle at the musculotendinous junction: a case report. *J Hand Surg* (1997).