



U·P·O·J

Mehta Casting for Early Onset Scoliosis— Operative Technique

Todd Blumberg, MD
Susan Nelson, MD, MPH
Daniel Miller, MD
Andrew Gambone, MD
Joseph Monteleone
Patrick Cahill, MD

Introduction

Management of early onset scoliosis (EOS) is a challenging endeavor for the pediatric orthopedic surgeon. While a number of “growth friendly” spinal implants exist, including growing rods, Vertical Expandable Prosthetic Titanium Rib (VEPTR), and MAGnetic Expansion Control (MAGEC), these techniques have high complication rates¹, require multiple expansion procedures, and have been shown to result in unintended autofusion in nearly 90% of patients.² Additionally, growing constructs exhibit signs of diminishing returns with subsequent lengthening procedures³, reducing their effectiveness as the child ages.

Background

Many cases of infantile idiopathic scoliosis (IIS) resolve spontaneously as trunk and motor control rapidly develop in the neonate. However, for curves with documented progression treatment is recommended. Cotrel et al. managed EOS successfully with a casting method utilizing elongation, derotation, and flexion to correct the deformity⁴. Mehta adapted this technique to infantile scoliosis, finding 69% of patients completely resolved by an average age of 3.5 years when treated early.⁵ Serial casting technique for EOS relies on the principle of guided growth, improving the deformity in the cast and allowing continued growth of the child to aid in the correction. Although serial casting has been associated with complete resolution of deformity in patients with IIS, the goal of casting is not necessarily complete cure. For more severe deformity or patients with other types of scoliosis, casting can be an effective tactic to delay surgical treatment with growing instrumentation^{6,7}.

Preoperative Evaluation and Indications

Mehta casting is indicated in patients with progressive curves beginning as young as 12 months of age. Patients with EOS should be evaluated with a thorough clinical history and physical exam. Appropriate imaging, including PA and lateral scoliosis radiographs, should be obtained as well as an MRI to evaluate for neural axis anomalies such as a tethered cord, syrinx, or Chiari malformation. Appropriate referrals for patients with syndromic scoliosis

and evaluation of the cardiac and renal systems by the pediatrician are recommended. Contraindications to serial casting include resolving/non-progressive scoliosis and inability to receive general anesthesia. Families should be warned about the potential for skin complications. The expectations regarding curve improvement, need for a minimum commitment of 12 months of casting, and likelihood of additional procedures as the child grows, especially for older children and those with larger curves, should be discussed.

Procedure

The patient is administered a general anesthetic and intubated while supine on a stretcher. Laryngeal mask airway (LMA) is contraindicated due to the high peak inspiratory pressure that are created while the cast is being molded. A silver impregnated tank or other liner is applied. Tubular stockinette is fastened above the iliac crests and halter traction used at the chin to assist in elongation. The patient is moved to the Mehta table and arms are abducted to 90 degrees, padded, and secured with cast padding. Halter traction is connected and the legs are placed into a sling, allowing for both a mild flexion and traction force to be applied to the patient (Figure 1). Cast padding is applied and imaging is reviewed to plan hand positioning for derotation molding. Contrary to adolescent idiopathic scoliosis, the majority of infantile idiopathic curves are left major thoracic curves with the apex at the lower thoracic spine. Three to four layers of four-inch plaster are applied to the torso followed by the derotation molding. The surgeon derotates the thorax with one hand posteriorly at the apex of the deformity, just lateral to the costovertebral junction, and one hand anteriorly over the rib prominence. An assistant provides counter pressure on the upper chest/shoulder and another holds and molds the pelvis at the iliac crests to allow maximum derotation. A mirror at the base of the table is utilized to evaluate and adjust the hand position during derotation. After the plaster has set, fiberglass cast material is overwrapped (Figure 1).

Windows are cut from the front and back of the cast to allow for abdominal and chest wall expansion (Figure 2), with placement of the

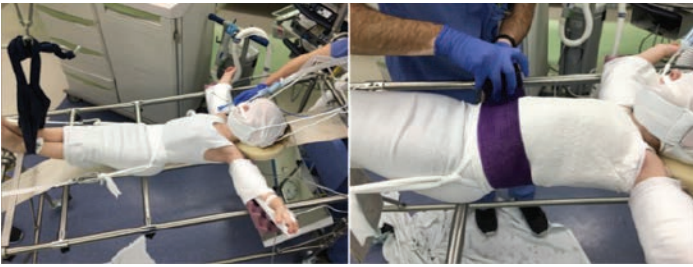

Figure 1. The patient is positioned on the Mehta table with arms abducted and padded. Halter traction is applied to the head, and stockinette overlying the iliac crest provides a traction force with the legs flexed, producing elongation and flexion. The plaster cast is applied and molded to derotate the rib cage.

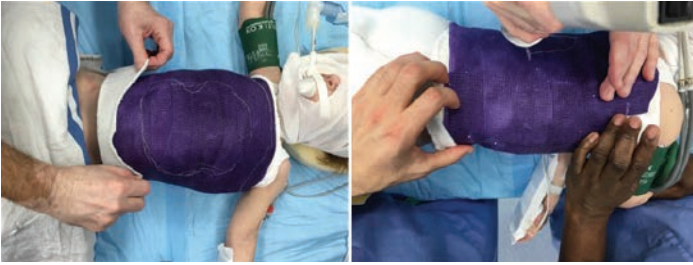

Figure 2. After the cast is applied, the patient is transferred back to the stretcher where windows in the cast are made to allow for improved respiratory mechanics. The posterior window is removed on the concavity of the deformity, in this case, the right side of the chest only.

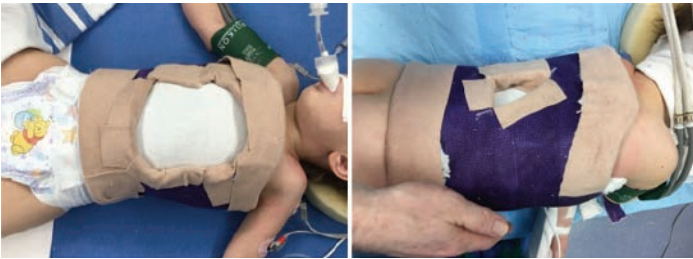

Figure 3. Moleskin is applied to the edges of the cast, covering all fiberglass surfaces.

posterior window on the opposite side of the curve. Cast edges are then padded with moleskin to prevent skin irritation (Figure 3).

Postoperative Protocol

Upright radiographs are obtained prior to discharge to assess the correction (Figure 4). Patients are typically admitted after the first cast to monitor respiratory status and provide cast care teaching. Subsequent cast changes are performed as outpatient procedures every 2-3 months. Casting is discontinued when curve resolution or stabilization occurs, or if serially casting fails to halt curve progression. After successful

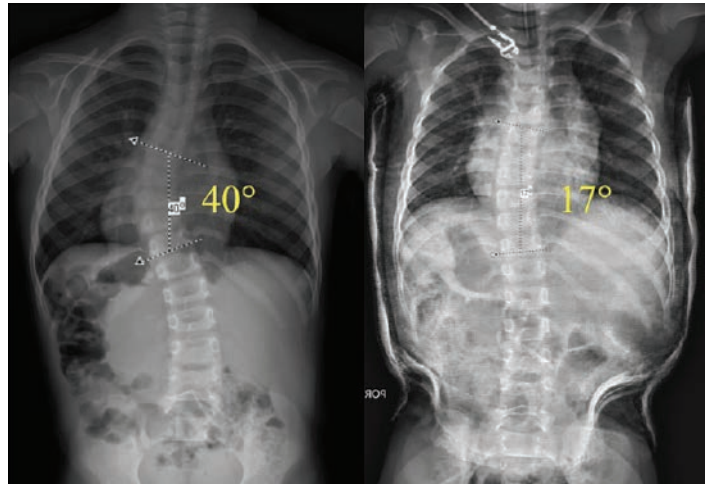


Figure 4. Pre- and post-casting imaging demonstrating a left thoracic curve (T9 apex) with 40 degrees of deformity in the coronal plane. Following cast application, the coronal deformity has decreased to 17 degrees and the thoracic spine has been largely de-rotated. Note the well-padded supra-pelvic mold.

cast treatment, a brace is utilized to prevent progression with continued growth.

Discussion

Mehta casting is an effective and reliable method to address early onset scoliosis. This technique can be curative for infantile idiopathic curves, and can help delay surgery in children with other forms of early onset scoliosis. It may offer an alternative to “growth friendly” spinal implants, which have a high rate of complication.

References

1. Bess S, Akbarnia BA, Thompson GH, Sponseller PD, Shah SA, El Sebaie H, *et al.* Complications of growing-rod treatment for early-onset scoliosis: analysis of one hundred and forty patients. *J Bone Joint Surg Am.* 2010;92(15):2533-43.
2. Cahill PJ, Marvil S, Cuddihy L, Schutt C, Idema J, Clements DH, *et al.* Autofusion in the immature spine treated with growing rods. *Spine (Phila Pa 1976).* 2010;35(22):E1199-203.
3. Sankar WN, Skaggs DL, Yazici M, Johnston CE, 2nd, Shah SA, Javidan P, *et al.* Lengthening of dual growing rods and the law of diminishing returns. *Spine (Phila Pa 1976).* 2011;36(10):806-9.
4. Cotrel Y, Morel G. [the Elongation-Derotation-Flexion Technic in the Correction of Scoliosis]. *Rev Chir Orthop Reparatrice Appar Mot.* 1964;50:59-75.
5. Mehta MH. Growth as a corrective force in the early treatment of progressive infantile scoliosis. *J Bone Joint Surg Br.* 2005;87(9):1237-47.
6. Demirkiran HG, Bekmez S, Celilov R, Ayzav M, Dede O, Yazici M. Serial derotational casting in congenital scoliosis as a time-buying strategy. *J Pediatr Orthop.* 2015;35(1):43-9.
7. Fletcher ND, McClung A, Rathjen KE, Denning JR, Browne R, Johnston CE, 3rd. Serial casting as a delay tactic in the treatment of moderate-to-severe early-onset scoliosis. *J Pediatr Orthop.* 2012;32(7):664-71.