



Tips and Tricks: Utilization of an Articulated Tensioning Device to Treat a Humeral Shaft Nonunion: Technical Considerations and Case Example

Lisa G. M. Friedman, MD, MA
Stephen Barchick, MD
Chielozor Okafor, MD
Bradley Osemwengie, MD
Samir Mehta, MD

Department of Orthopaedic Surgery,
University of Pennsylvania

Introduction

Humeral shaft fractures compromise approximately 3% of fractures and can be treated both operatively and non-operatively with good success.^{1,2} However, some studies cite a nonunion rate as high as 33% when these injuries are treated non-operatively and up to 10% when treated operatively.³ The risk factors for non-union are numerous, including patient factors, the fracture morphology, and the biologic environment. Before surgery for a non-union, metabolic factors, such as endocrine abnormalities, must be addressed. Patients who smoke should be counseled about quitting. In addition, it is imperative to ensure there is no infection contributing to the lack of bone healing by performing a laboratory work-up consisting of white blood cell count, erythrocyte sedimentation rate and C-reactive protein. If there is concern for infected nonunion, a biopsy may be indicated.⁴ Non-unions can be classified as atrophic, with a paucity of callus formation due to inadequate local biology; hypertrophic, with abundant callus formation but with lack of union at the fracture site owing to a lack of stability; or oligotrophic, with minimal callus at the fracture site due to significant displacement.⁴ Non-unions can further be classified as septic or aseptic based on the presence of infection at the fracture site.⁵

While non-operative treatment is appropriate for most patients sustaining a humeral shaft fracture, anatomic factors such as transverse fracture pattern or concomitant glenohumeral arthritis and patient factors such as Vitamin D deficiency or use of certain medications can increase the risk of developing a non-union.^{3,5} Non-operative treatment is typically by way of functional brace, once swelling subsides, to provide compression of the soft tissue at the fracture site to maintain alignment, and the fractures must be radiographically surveilled to ensure the fracture heals. According to Driesman et al., mobility at a humeral fracture site at 6 weeks is 99% specific for predicting future fracture non-union.⁶

There are a variety of techniques described for operative fixation of humeral shaft fractures. Intramedullary nailing, bridge fixation, and compression plating, through open and minimally invasive techniques have been described, as well as external fixation in damage control situations. Open reduction internal fixation with a 4.5mm compression plate has the benefit of visualizing an anatomic reduction as well as the ability to find and protect the radial nerve, pending the approach and extent of dissection. Open reduction also provides access to augment the fracture site with autogenous bone graft or biologic augmentation. An intramedullary device can minimize periosteal stripping as well as provide for secondary healing in comminuted fractures in which an anatomic reduction would be challenging. Non-union rates are similar between the two techniques, but intramedullary nailing is associated with a higher overall complication rate and shoulder pain, while plating is associated with faster functional recovery, faster time to union, improved shoulder range of motion, though a higher rate of radial nerve palsy.⁷⁻¹⁰

In the case of humeral shaft non-union, the gold standard for treatment is compression plating. In a systematic review, Peters et al. found a 98% union rate for humeral non-unions treated with plate fixation with autologous bone grafting, with a complication rate of 12%.¹¹ As with acute fractures, the benefits of this technique are that it allows for compression at the fracture site, correction of malalignment, and access to the fracture site to incorporate various types of osteoconductive, osteoinductive, and osteogenic substances.^{12,13} In particular, the purpose of compression is to minimize motion between the fracture fragment, thereby eliminating strain and optimizing primary bone healing.

The amount of compression across a fracture site is important with regards to minimizing strain and optimizing the healing environment. In a study by Lucas et al., compression was measured across a fracture site created in composite sawbone models

utilizing various techniques. They found that the use of an articulating tensioning device created more compression across the fracture site than utilizing a Verbrugge clamp with a push-pull screw located outside of the plate. Both techniques provided more compression than a standard dynamic compression technique.¹⁴

Case Example

A 48-year-old, right-hand dominant male presented to an outside hospital two days after a fall onto his arm. He was diagnosed with a closed, transverse midshaft humerus fracture and temporized with a coaptation splint. Of note, the patient had a significant history of seizure disorder, smoking, and hypertension. Approximately 1 week later, he was seen in the outside clinic and was fitted with a Sarmiento brace. Approximately 2 weeks after the injury, he presented again with an ill-fitting Sarmiento that was applied more proximally. Imaging showed minimal callus formation at that time and no significant changes in alignment. This was also the case when he followed up 4 weeks after the injury. The patient was given a bone stimulator and continued in the Sarmiento brace. He was seen again 9 weeks after the injury with similar findings. He was seen 14.5 weeks after his injury after sustaining two seizures and hitting his injured arm. Images were unchanged. The patient's smoking increased his risk for non-union by causing vasoconstriction and reducing capacity to carry oxygen to tissues.¹⁵ The patient was also at increased risk of fracture both due to his seizure disorder as well as the anti-epileptic medications used to treat it.¹⁶ His seizures were treated with phenobarbital

and valproate acid, increasing his risk for non-union by decreasing bone mineral density.¹⁷

The patient was referred to our outpatient trauma clinic for evaluation of his humerus, now sixteen weeks after his initial presentation. The patient was neurovascularly intact, including the radial nerve, and had tenderness at the fracture site. Radiographs showed no interval callus formation (Figure 1). The patient was scheduled for surgery two weeks after he was seen in clinic, 18 weeks after his injury.

The patient was taken to the operating room and placed supine on a reversed radiolucent bed with a radiolucent board to hold the operative extremity in appropriate position for surgical exposure and utilization of fluoroscopy. Antibiotics were administered, the arm was prepped and draped in sterile fashion. An anterolateral approach to the humeral shaft was utilized. The fascia was incised, and the biceps was taken medially. The brachialis was identified and split in the interval between the two innervating nerves (musculocutaneous medially and radial nerve laterally), revealing a fibrous nonunion. The non-union was debrided until bleeding bone edges were identified. With bleeding bone edges, the edges were approximated under direct visualization.

For reduction, a 2.5mm drill bit was utilized to drill unicortical holes on each side of the nonunion to place a modified point-to-point clamp to both reduce and initially compress across the fracture site (Figure 2). A second modified point-to-point was applied in similar fashion to hold the reduction in compression on the opposite side to prevent eccentric reduction and far-side gapping. Biplanar

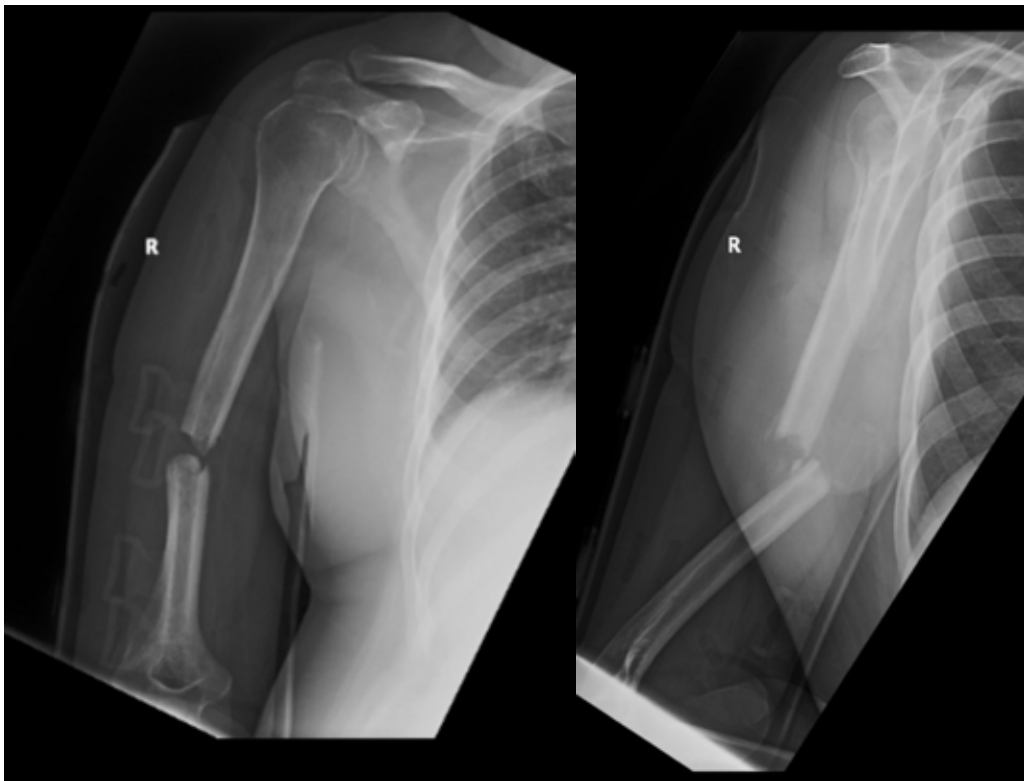


Figure 1. AP and Lateral of the humerus demonstrates a transverse mid-diaphyseal humeral shaft fracture non-union 16 weeks after initial injury.

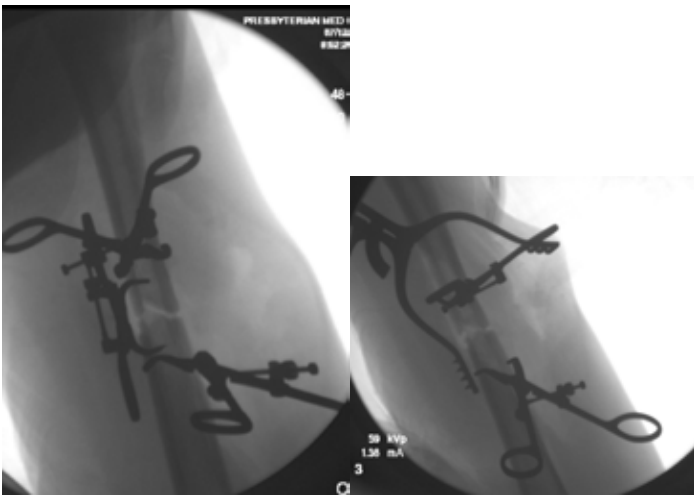

Figure 2. Intraoperative fluoroscopic images demonstrating a debrided non-union site and a reduced fracture held together by a single modified point-to-point exhibiting increased fracture gap on the far side. This is addressed by a second modified point-to-point to clamp on the far side to prevent eccentric compression.

fluoroscopy was utilized to ensure appropriate alignment and cortical width matching on bone ends of the fracture.

A 9-hole, 4.5mm LC-DCP implant was utilized and placed with the central hole over the fracture site. The plate was contoured slightly to prevent gapping of the far cortex when applied to bone in compression mode. The plate was applied to the bone and pinned on both sides (Figure 3). The first screw was placed distal to the fracture site to create a distal bone-plate construct. The second screw placed in the bone was proximal to the plate to utilize the articulated tensioning device (ATD). With appropriate spacing between the proximal edge of the plate, the screw and the ATD, the ATD was utilized to compress across the fracture site and a screw was placed eccentrically in the proximal end of the plate, proximal to the fracture site. The strain gauge on the device utilizes

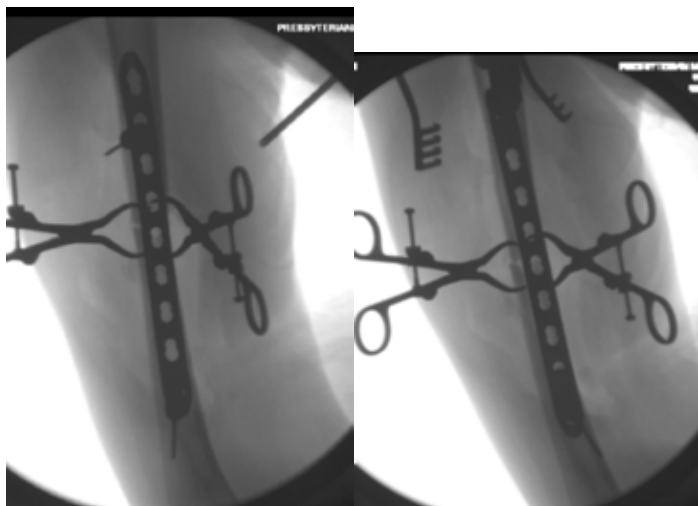


Figure 3. Intraoperative fluoroscopic images demonstrating a 9-hole, over-contoured anterolateral plate was utilized and pinned on both sides with two clamps reducing and symmetrically compressing the nonunion.

a color-coding system: green to yellow to red to indicate when appropriate tension has been applied (Figure 4).¹⁸ The device was tensioned through the red section, providing compression across the fracture site. (Figure 5). The third screw was placed centrally in a hole distal to the fracture site, followed by the fourth screw which was placed eccentrically in the proximal end of an oblong hole on the proximal end of the fracture to achieve additional compression of the nonunion site.

Multiple screws were placed on either side of the fracture site utilizing a compression technique to further provide more compression. It is recommended that one obtains six to eight cortices of fixation proximal and distal to the fracture site.^{2,19} Non-locking screws were placed proximally and distally and the articulating tensioning device was removed. The fracture was reduced and hardware was appropriately placed (Figure 6). Local autogenous bone

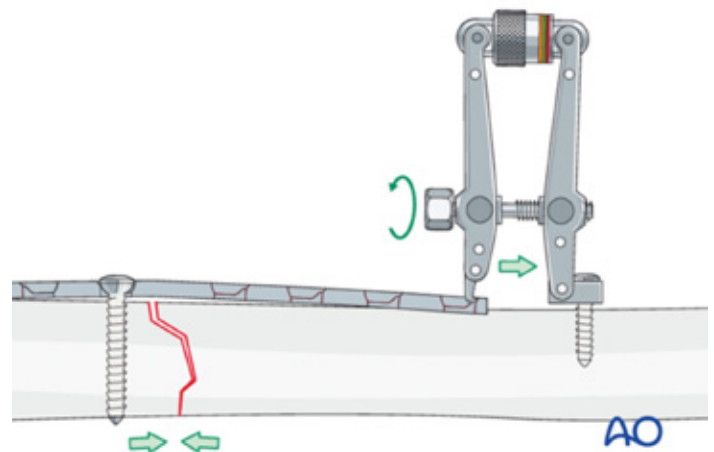


Figure 4. Schematic diagram demonstrating the use of an articulated tensioning device.²⁰

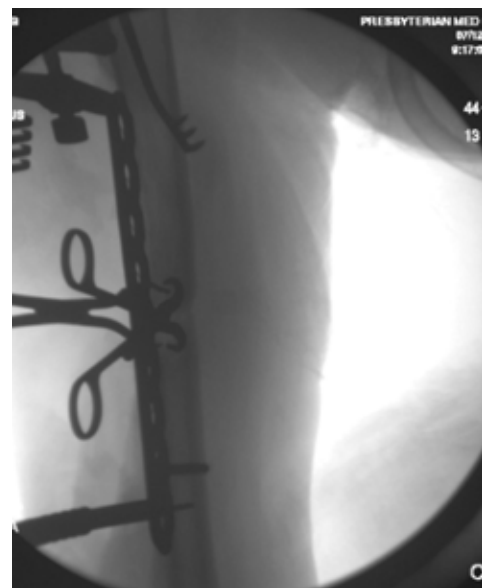


Figure 5. Intraoperative fluoroscopic image demonstrating an articulated tensioning device that was placed proximally and utilized to provide compression through the fracture site.

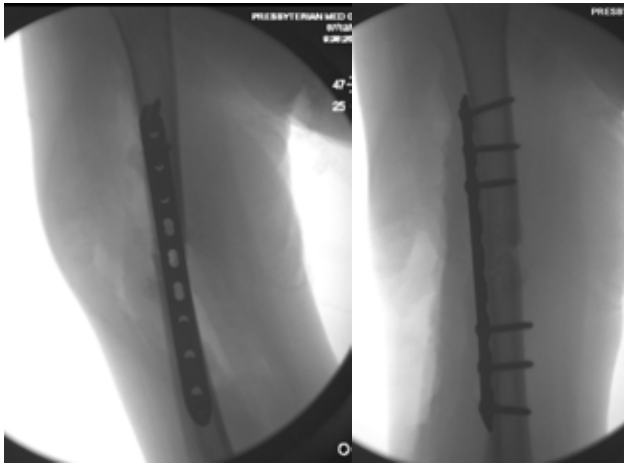


Figure 6. Fluoroscopic images demonstrate the final construct with a reduced, compression fracture site and hardware in appropriate position.

as well as Vivigen (DePuy Synthes, Raynham, MA (frozen corticocancellous bone matrix, demineralized bone, and bone cells) were applied. The wound was closed with a multilayer closure using 2-0 vicryl, 3-0 vicryl and staples. The patient recovered uneventfully in the post-anesthesia care unit and was discharged home the same day (Figure 7). The patient was made weight bearing as tolerated on the injured extremity and was give 325 mg of aspirin twice daily for venous thrombosis prophylaxis and a short course of oral antibiotics for infection prophylaxis.

The patient followed-up at two-weeks for an incision check and staple removal at which time he began physical therapy. He remained neurovascularly intact. At six-weeks postoperatively, radiographs demonstrated interval healing at the fracture site with hardware in appropriate position (Figure 8). The patient weaned out of his sling in the weeks following surgery and he continued with physical therapy. He was discharged from the practice six weeks after surgery to follow up on as add-needed basis given his successful outcome.

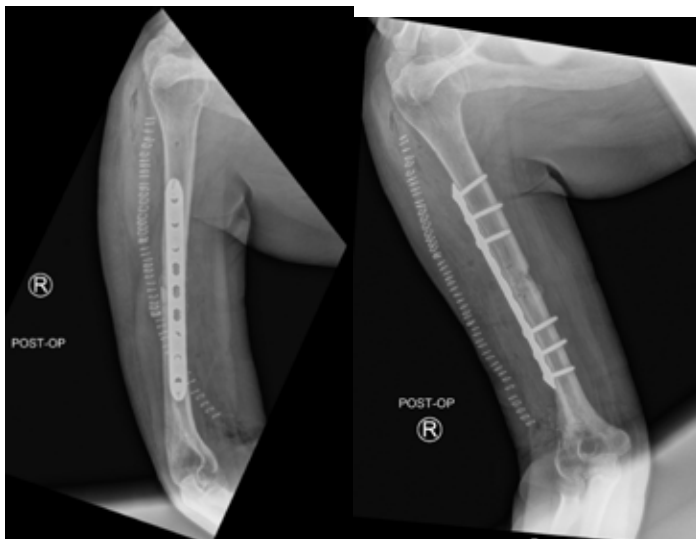


Figure 7. AP and lateral radiographs of the humerus were taken in the post-anesthesia care unit demonstrating the final construct.

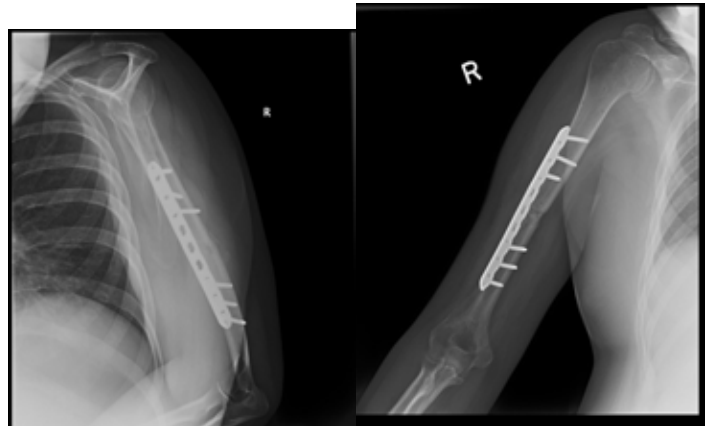

Figure 8. AP and lateral radiographs of the humerus at six-week follow up demonstrates interval healing of the fracture site and appropriately aligned hardware.

Conclusion

This case demonstrates the use of an articulated tensioning device to treat humeral shaft non-unions. By augmenting compression across the fracture site, thereby eliminating strain, this technique can enhance healing. While non-union is a common outcome in non-operatively treated humeral shaft fractures, an articulated tensioning device is a valuable tool, providing more compression than other methods, thereby enhancing bone healing.

References

1. Volgas DA, Stannard JP, and Alonso JE. Nonunions of the humerus. *Clin Orthop Relat Res.* 2004;(419):46-50.
2. Walker M, Palumbo B, Badman B, et al. Humeral shaft fractures: A review. *J Shoulder Elbow Surg.* 2011;20(5):833-844.
3. Oliver WM, Searle HKC, Ng ZH, et al. Factors associated with humeral shaft nonunion. *J Shoulder Elbow Surg.* 2021;30(10):2283-2295.
4. Hak DJ, Fitzpatrick D, Bishop JA, et al. Delayed union and nonunions: Epidemiology, clinical issues, and financial aspects. *Injury.* 2014;45 Suppl 2:3
5. Naclerio EH and McKee MD. Approach to humeral shaft nonunion: Evaluation and surgical techniques. *J Am Acad Orthop Surg.* 2022;30(2):50-59.
6. Driesman AS, Fisher N, Karia R, Konda S, et al. Fracture site mobility at 6 weeks after humeral shaft fracture predicts nonunion without surgery. *J Orthop Trauma.* 2017;31(12):657-662
7. Heineman DJ, Bhandari M, Poolman RW. Plate fixation or intramedullary fixation of humeral shaft fractures—an update. *Acta Orthop.* 2012;83(3):317-318.
8. Den Hartog D, Mahabier KC, Van Bergen SH, et al. Functional and clinical outcomes after plate osteosynthesis versus intramedullary nailing of a humeral shaft fracture: The results of the HUMMER multicenter, prospective cohort study. *J Bone Joint Surg Am.* 2023;105(14):1101-1111.
9. Ouyang H, Xiong J, Xiang P, et al. Plate versus intramedullary nail fixation in the treatment of humeral shaft fractures: An updated meta-analysis. *J Shoulder Elbow Surg.* 2013;22(3):387-395.
10. Amer KM, Kurland AM, Smith B, et al. Intramedullary nailing versus plate fixation for humeral shaft fractures: A systematic review and meta-analysis. *Arch Bone Jt Surg.* 2022;10(8):661-667.
11. Peters RM, Claessen FMAP, Doornberg JN, et al. Union rate after operative treatment of humeral shaft nonunion—A systematic review. *Injury.* 2015;46(12):2314-2324.
12. Padhye KP, Kulkarni VS, Kulkarni GS, et al. Plating, nailing, external fixation, and fibular strut grafting for non-union of humeral shaft fractures. *J Orthop Surg (Hong Kong).* 2013;21(3):327-331.
13. Li Y, Wang C, Wang M, Huang L, et al. Postoperative malrotation of humeral shaft fracture after plating compared with intramedullary nailing. *J Shoulder Elbow Surg.* 2011;20(6):947-954. doi: 10.1016/j.jse.2010.12.016.
14. Lucas JF, Lee MA, and Eastman JG. Optimizing compression: Comparing eccentric plate holes and external tensioning devices. *Injury.* 2016;47(7):1461-1465.

15. **Copuroglu C, Calori GM, and Giannoudis PV.** Fracture non-union: Who is at risk? *Injury.* 2013;44(11):1379-1382.
16. **Pack AM, Morrell MJ.** Epilepsy and bone health in adults. *Epilepsy Behav.* 2004;5 Suppl 2:24.
17. **Svalheim S, Roste LS, Nakken KO, et al.** Bone health in adults with epilepsy. *Acta Neurol Scand Suppl.* 2011;(191):89-95.
18. **Depuy Synthes.** 4.5 mm LCP proximal femur plates: surgical technique. <http://synthes.vo.llnwd.net/o16/LLNWMB8/US%20Mobile/Synthes%20North%20America/Product%20Support%20Materials/Technique%20Guides/DSUSTRM09161039%20Rev%20B.pdf>. Website. Updated 2021.
19. **Mistry MR, Tat J, Husain R, et al.** Inadequate proximal screw fixation increases risk of failure following plate fixation of diaphyseal humerus fractures. *J Orthop Surg Res.* 2023;18(1):142-2.
20. **Camuso M, and White R.** AO surgery reference. ORIF - compression plating. <https://surgeryreference.aofoundation.org/orthopedic-trauma/adult-trauma/tibial-shaft/simple-fracture-transverse/orif-compression-plate#fixation> Website. Updated 2012.